



Review article

The management of talar osteochondral lesions - Current concepts

Tian Lan ^{a, c}, Helen S. McCarthy ^{a, c}, Charlotte H. Hulme ^{a, c}, Karina T. Wright ^{a, c},
Nilesh Makwana ^{b, c, *}

^a Spinal Studies & Cartilage Research Group, Robert Jones and Agnes Hunt Orthopaedic Hospital, NHS Trust, Oswestry, UK

^b Robert Jones and Agnes Hunt Orthopaedic Hospital, NHS Trust, Oswestry, UK

^c School of Pharmacy and Bioengineering, Keele University, UK



ARTICLE INFO

Article history:

Received 1 April 2021

Accepted 5 April 2021

Available online 23 April 2021

Keywords:

Ankle

Talus

Osteochondral lesion

Osteochondral defect

Treatment

ABSTRACT

Osteochondral lesions of the talus (OLTs) are a common complication following trauma, involving both the articular cartilage and the underlying subchondral bone, with variable aetiologies and often presenting with non-specific symptoms. Diagnosis of OLTs requires a combination of clinical assessment and imaging and despite many different treatment options, there is no generalised consensus regarding which option is the most effective. Left untreated, OLTs risk progressing to osteoarthritis. Acute non-displaced OLTs can be treated non-operatively. However, OLTs refractory to non-surgical care for three to six months may be suitable for surgical care. In these cases, conservative treatments are often unsuccessful, particularly for larger and more severe defects and so the majority require surgical intervention. Although bone marrow stimulation techniques remain the “gold standard” for lesions <150 mm², there still requires a need for better long term clinical data and cost-benefit analyses compared with other treatment options. Biological attempts at either regenerating or replacing the articular cartilage are however demonstrating some promising results, but each with their own advantages and disadvantages. In this review, we summarise the clinical management of OLTs and present the current concepts of different treatment regimes.

Crown Copyright © 2021 Published by Elsevier, a division of RELX India, Pvt. Ltd on behalf of International Society for Knowledge for Surgeons on Arthroscopy and Arthroplasty. This is an open access article under the CC BY license (<http://creativecommons.org/licenses/by/4.0/>).

1. Introduction

Osteochondral lesions of the talus (OLTs), also known as talar osteochondral defects, include many varieties of pathologies such as osteochondritis dissecans, transchondral fractures and osteochondral fractures. In general, OLTs refer to any defect of the ankle articular cartilage and underlying subchondral bone.¹ OLTs are mainly associated with trauma, with the majority of defects occurring in young people aged between 20 and 40 years, following ankle sprains or fractures.² They can be diagnosed by plain radiography, computerized tomography (CT), magnetic resonance imaging (MRI) and arthroscopy; OLT classifications among these diagnostic techniques also vary.³ Patients with symptomatic OLTs will normally suffer from prolonged pain, swelling, locking and

catching of the ankle joint. Acute non-displaced OLTs can be treated non-surgically with successful results in up to 50% of cases.^{4,5} Due to the low healing capacity of articular cartilage, conservative treatments such as immobilisation, rest and restriction of activities do not have a good performance in ankle restoration in late stage symptomatic OLT patients.⁶ Untreated OLTs may contribute to the development of early-stage osteoarthritis (OA) and lead to the severe disability.^{7,8} Bone marrow stimulation is still a gold standard among surgical interventions for lesions <150mm², but it cannot promise good long-term results.^{1,9} Newer, novel cell-based therapies are developing rapidly, aiming for safe, cost-effective and improved long-term results.

2. Aetiology

The aetiology of OLTs is still controversial but are more common in young and active patients (20–40 years old) following an ankle sprain or trauma.^{2,10} It is widely accepted that OLTs are caused by both traumatic and nontraumatic events with up to 50% of ankle sprains and over 70% of ankle fracture cases leading to the

* Corresponding author. Robert Jones and Agnes Hunt Orthopaedic Hospital, NHS Trust, Oswestry, SY10 7AG, UK.

E-mail addresses: tian.lan@nhs.net (T. Lan), helen.mccarthy6@nhs.net (H.S. McCarthy), charlotte.hulme@nhs.net (C.H. Hulme), karina.wright1@nhs.net (K.T. Wright), nilesh.makwana@nhs.net (N. Makwana).

development of osteochondral lesions.^{7,11} A study by Tol et al. (2000),¹² demonstrated 93% of patients with lateral lesions had a history of trauma, compared to only 62% with medial lesions. According to Berndt and Harty,¹³ the mechanism of injury in lateral lesions, is associated with ankle joint dorsiflexion and inversion, while in medial lesions it is associated with ankle plantarflexion and inversion. OLTs without trauma history could possibly be caused by repetitive microtrauma, ischemia, subsequent avascular necrosis, genetic predisposition and endocrine or metabolic factors.¹⁴

Depending on their anatomical location, OLTs are divided into different types. Posteromedial and anterolateral OLTs were traditionally thought to be the most common OLTs.¹³ Raikin et al. (2007) examined 424 patients by MRI based on a 9-zone anatomic grid system (Fig. 1), and found that the majority of lesions (53%) were located in zone 4 (centromedial), and that the second most common lesion location was zone 6 (centrolateral).¹⁵ Another study, however, demonstrated the opposite with regards symptomatic and operatively treated lesions, with the centrolateral region being twice as common as the centromedial region of the talar dome.¹⁶ Despite this, these studies demonstrate that the centrolateral and centromedial areas of the talar dome are the most common locations for OLTs. In addition, it has been shown in several studies that medial lesions are generally larger and deeper while lateral lesions are smaller and shallower.^{13,15,16} However, lateral lesions tend to be more symptomatic than medial lesions, possibly due to the higher baseline contact pressure found in the centrolateral area compared to the centromedial area of the ankle joint.¹⁶

It has been demonstrated that the posteromedial and anterolateral regions of the talar dome have the thickest articular cartilage, as evidenced by quantitative cartilage thickness measurements of 12 cadaveric ankle joints by high resolution stereophotography.¹⁷ The authors of this study have related this finding to an adaptive response of the tissue in this region to the

greatest mechanical stress, and claimed that these results are consistent with the most common sites of OLTs.¹⁷ However, other studies suggest that the posterolateral region of the talar dome has the thickest articular cartilage and that the anterolateral region has the thinnest articular cartilage, as assessed by confocal microscopy and MR imaging with 3D modelling respectively.^{18,19} Further, Sugimoto et al. (2005) concluded that articular cartilage in the medial corner of the talar dome showed the greatest thickness, while the lateral gutter of the talar dome showed the least thickness, as assessed radiographically.²⁰ Taken together, although there is no complete agreement on the thickness of cartilage in specific regions, the cartilage thickness has been shown to vary in all studies across the talar dome, and its relationship with the mechanism of OLT development requires further investigation.

Compared to the knee, the ankle is anatomically different: it has a smaller articular contact area than the knee, and over 60% of the talar dome is covered by hyaline cartilage. Ankle cartilage has a higher dynamic stiffness due to the higher proteoglycan content, which contributes to stability when weightbearing or loading.²¹ The average cartilage thickness of the ankle is almost two folds thinner than the knee, however a study showed that the ankle has a relatively higher proportion of the superficial zone of cartilage, which indicates that ankle has stronger protection than the knee when weightbearing.²² In addition, ankle articular cartilage has undetectable levels of matrix metalloproteinase-8 (MMP-8) compared to knee articular cartilage, reducing endogenous degradation of extracellular matrix proteins.²³ From a biomechanical point of view, the main movements of the ankle joint are rolling and rotating, while the knee experiences higher shear forces from its rolling, sliding and rotating movements.²⁴ Although the development of ankle OA is considered to be associated with untreated OLTs,^{7,8} the incidence of OA in the ankle is relatively low; around 15% of adults are affected by OA worldwide, however, only 1% of this is ankle OA.²⁵ In a 21-year follow up study, Bauer et al. (1987) found that only two out of 30 patients' OLTs had progressed on to develop OA.²⁶ According to Günther et al. (1998), 67% of knee OA cases were primary origin,²⁷ while Valderrabano et al. (2008) reported that primary ankle OA only accounts for 9% of cases, whilst 78% of OA cases were posttraumatic.²⁵ In conclusion, the ankle develops less OA than the knee,²⁸ with ankle OA developing mainly post-traumatically and knee OA developing idiopathically.²⁴

3. Diagnosis and evaluation

Pain, swelling and stiffness are the most common complaints of presenting patients with OLTs, occurring particularly with high levels of activity such as sport, but rarely present at rest.²⁹ Occasionally, there may also be mechanical symptoms present such as locking and catching.³ Patients will often relate the pain experienced to a history of either a single trauma or recurrent sprains. Often the initial OLT is misdiagnosed as an ankle sprain.³⁰ Chronic OLTs present with non-specific symptoms, in these cases, physical examination may show an effusion, decreased range of motion, general tenderness, and pain with inversion or dorsiflexion.²⁹ In general, patients often describe a deep-seated pain with more chronic OLTs compared with a more superficial pain with synovitis.³¹ Of course, the absence of physical signs and symptoms on examination does not exclude the presence of OLTs, highlighting the importance of further clinical imaging investigations being required to confirm OLT diagnosis.³¹

Imaging modalities most commonly utilised in the clinic for the identification and diagnosis of OLTs include plain radiography, MRI and CT, each with their own benefits, drawbacks and classification systems (Table 1). Initially, plain radiographs are often used upon first presentation usually taken in anterior-posterior (AP) mortise

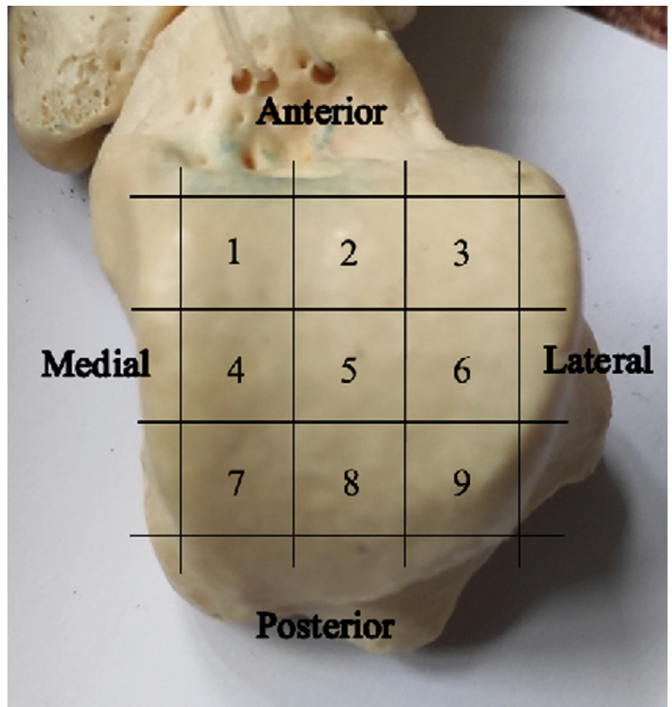


Fig. 1. Anatomical 9 zone grid system of the talar dome.¹⁵ The talar dome is divided into 9 equal zones, with zones 1, 2 and 3 located anteriorly and zones 3, 6 and 9 located laterally.

Table 1

Overview of the classification systems used across the different assessment modalities used in the diagnosis of OLTs. OC = osteochondral fragment; SCB = subchondral bone.

X-Ray	MRI	CT	Arthroscopy	
Berndt and Harty ¹³	Hepple ³⁴	Ferkel ³⁶	ICRS ³⁷	Cheng-Ferkel ³⁸
I – subchondral compression	1 – articular damage only	I – cystic lesion, intact overlying articular cartilage	1 – superficial zone softening or fissure	A – smooth and intact cartilage, but soft
II – partially detached OC fragments	2a – Articular cartilage damage with subchondral fracture (– oedema)	IIA – cystic lesion with articular surface communication	2 – lesions extend <50% depth	B – rough articular surface
III – fully detached OC fragments	2b – Articular cartilage damage with subchondral fracture (+oedema)	IIB – overlying non-displaced OC fragment	3 – lesions extend >50% depth but not into SCB	C – fissures and fibrillations present
IV – displaced OC fragments	3 – detached non-displaced OC fragment	III – non-displaced OC fragment with lucency	4 – lesion extends into the SCB	D – cartilage flap or exposed SCB
	4 – detached and displaced OC fragment	IV – displaced OC fragment		E – loose, non-displaced fragments
	5 – subchondral cysts			F – displaced fragment

view and lateral weight-bearing views of the ankle. In the acute injury a trauma series is often taken. Radiographs have relatively low sensitivity and are often unclear, missing over 40% of cases.^{31,32}

The Berndt and Harty radiography score is a 4-stage classification system that assesses the initial subchondral compression (stage I) and osteochondral fragments being either partially detached (stage II), completely detached (stage III) or displaced (stage IV; Table 1).¹³

MRI is more able to clearly visualise soft tissues such as articular cartilage, synovium and tendons, making it advantageous in detecting and characterising OLTs.³¹ It is often the imaging modality of choice following inconclusive plain radiographs or continuation of symptoms. However, MRI is less able to assess bony changes and can make it difficult to fully assess the true status of the subchondral bone and the exact lesion dimensions.³³ OLTs on MRI are classified according to the 5-stage Hepple MRI classification system,³⁴ where stage 1 is articular cartilage damage only, stage 2 is cartilage damage with subchondral fracture (this is further categorised as either acute (2a) or chronic (2b) dependent upon the presence of oedema), stages 3 and 4 include detached non-displaced and displaced osteochondral fragments, respectively and stage 5 is the presence of subchondral cysts (Table 1).

CT on the other hand provides a far superior assessment of the subchondral bone compared to MRI and can therefore more accurately predict the depth of the OLT unless it is an early lesion, which is characterised by changes in the articular cartilage.³⁵ Performing a CT scan can provide the surgeon with the finer details required for accurate surgical planning.³⁵ OLTs on CT are classified according to the Ferkel system where stage I is the presence of a cystic lesion but with intact overlying articular cartilage,³⁶ stage IIA is where the cystic lesion communicates with the articular surface and stage IIB includes an overlying non-displaced osteochondral fragment, stage III is a non-displaced fragment with lucency beneath it and stage IV is a displaced fragment (Table 1).

Arthroscopy is also an effective method for visualising and investigating OLTs. The ability to assess the entire joint in addition to probing the lesion can provide the most comprehensive evaluation in deciding the most appropriate treatment regime. Arthroscopic evaluation of OLTs uses the International Cartilage Repair System (ICRS) grading,³⁷ which is a standardised grading system. Grade 1 lesions involve the superficial zone with softening or fissure, Grade 2 lesions extend less than 50% of the depth, Grade 3 greater than 50% in the depth but not to the subchondral bone as in Grade 4 (Table 1). Cheng-Ferkel grading is another arthroscopic grading system used in OLT evaluation, Grade A lesions present smooth and intact cartilage with a soft or ballottable arthroscopic appearance, Grade B lesions show a rough surface, Grade C lesions appear fibrillations or fissures, Grade D lesions have a flap present or bone exposed, Grade E lesions are loose and normally show non-displaced fragments and displaced fragments present in Grade F

lesions (Table 1).³⁸

4. Treatment and outcomes

The goal of any treatment strategy of course is to diminish debilitating symptoms such as pain and swelling and to improve function. The effectiveness of each strategy, however, is variable and often the strategy adopted is based not only on the type and size of the defect but also preferences of the treating clinician. In acute non-displaced OLTs injuries conservative methods of treatment are usually considered with the intention of reducing the load on the damaged cartilage to resolve bone oedema or encourage healing of any detached fragments.³⁹ Methods include rest and/or restriction of activities with or without the use of non-steroidal anti-inflammatories (NSAIDs), short-term immobilisation in a cast or boot for approximately 6 weeks, followed by physiotherapy and progressive weight-bearing with a slow return to previous activities.^{1,29} Such conservative techniques are effective in only ~50% of cases.³⁹ Chronic symptomatic OLTs, acute fragmented OLTs and those refractory to conservative management should be considered for surgical intervention.¹ Acute displaced, symptomatic OLTs can be treated by open or arthroscopic methods, whereas large OLTs are usually fixed using headless cannulated screws or absorbable pins. Access to the ankle is restricted and this may require either a medial or lateral malleolar osteotomy for access. Small or fragmented lesions can simply be excised (Fig. 2). Symptomatic OLTs that are chronic or refractory to non-surgical measures should be considered for surgical intervention. Surgical interventions to treat OLTs are most commonly performed as arthroscopic interventions. The majority of procedures treat the OLTs through debridement of any damaged hyaline cartilage and underlying subchondral bone. The 'gold standard' treatment for lesions <150 mm² remains microfracture,^{1,9} which involves creating small holes in the subchondral bone to create a new blood supply, also resulting in innate mesenchymal stem or stromal cells (MSCs) entering the defect from the subchondral blood/marrow and stimulating healing of the cartilage. Microfracture benefits patients who require quick return to function, as this procedure requires early mobilisation of the joint through its' associated recommended rehabilitation programme.⁴⁰ Optimal clinical improvements of microfracture (based on Visual Analogue Scale (VAS) and American Orthopaedic Foot and Ankle Society (AOFAS) score) have been demonstrated at 24 months post-operatively.⁴¹ Recently published findings from both Kim et al. (2019) and Choi et al. (2020) indicate that microfracture results in mid-term improvements.^{41,42} When assessing 70 patients, 85% of patients showed some improvement 6 months after their microfracture, for whom their symptoms did not worsen from baseline at 3 years post-operatively.⁴¹ Further, in a study of 156 patients (165 ankles) improvement or maintenance of pain and

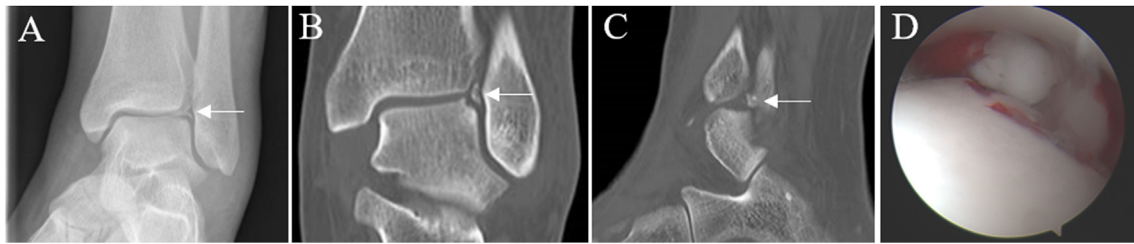


Fig. 2. 22-year-old female case presenting with an acute injury, with a history of a fall from a horse. X-ray (A) and CT (B–C) imaging demonstrated lateral talar dome OLTs (arrow). OLT fragment was excised arthroscopically (D).

functional scores (AOFAS; VAS; Short Form-36) compared with baseline scores could be demonstrated up to six years post-operatively.⁴² There does appear to be an inverse relationship between the size of the lesion and the outcome following microfracture. The critical size of the defect appears to be those that are less than 150 mm².^{41,43} Interestingly, a systematic review of 70 patients indicated that microfracture might also be effective as a treatment for non-primary OLTs.⁴⁴

In patients where lesions are observed within the subchondral bone but the hyaline cartilage is intact, retrograde drilling can be offered with the aim of treating the subchondral lesion whilst preserving overlying cartilage.⁴⁵ In the retrograde drilling procedure, articular cartilage is selected for entry into the talus and then a guidewire is directed into the lesion in a retrograde direction under x-ray control. This can also be under computer navigation to place the guide wire and direct the location of drilling.⁴⁵

Other interventions used to treat OLTs include those in which osteochondral transplants are inserted into small defect. These can be in the form of Osteochondral Autograft Transfers or Osteochondral Allograft Transplantations (OATs). In either of these procedures, non-weight bearing cartilage and subchondral bone is harvested as a cylindrical plug which is matched in size and area to the problem defect. To treat larger defects, mosaicplasty can be performed in which multiple smaller osteochondral (OC) plugs are taken and inserted into the defect(s).⁴⁶ For defects that are less than 1 cm², OATs are more commonly used in which the OC plugs are harvested from the patient themselves. Where defects are larger than 2 cm², OATs are carried out using arthrotomy. This relies on the harvest of OC plugs from cadaveric donors and subsequent sterilisation of the tissue prior to being transplanted into the patient's defect site. OATs have long been turned to as a surgical option for the treatment of OLTs, with these surgeries having been performed widely since 1992.⁴⁷ A number of systematic reviews have recently been published which aimed to determine the clinical outcomes following OATs in the ankle.⁴⁸ Pereira et al. (2021), found that in 12 studies, yielding 191 patients, there were no short-term complications following fresh OATs and that the graft survival rate was 86.6% (assessed by AOFAS and VAS score).⁴⁸ Autologous osteochondral transplants were also concluded to have good clinical outcomes (AOFAS, MRI and radiographs) at a mean of 62.8 months follow-up, although donor site morbidity was demonstrated in 18 of the 500 study participants.⁴⁹

More recently, surgeons have been investigating the potential of another allogeneic tissue donor source which uses particulated juvenile articular cartilage (PJAC).⁵⁰ These juvenile grafts are taken from donors typically younger than 13 years old. The only commercial graft available for this procedure at present, is DeNovo NT Natural Tissue Graft (Zimmer, Warsaw, IN, USA), marketed as a pre-packaged allograft consisting of immature chondrocytes in their innate extracellular matrix. These grafts can be used to treat focal defects up to 2 cm² with fibrin used to adhere the allograft in place. Similar to osteochondral allograft transfer, this procedure benefits

from removing the possibility of donor site morbidity that comes from an autologous tissue transfer procedure.⁵¹ PJAC treatment has been reported to produce articular cartilage, which is more akin to native tissue.⁵⁰ Aldawsari et al. (2021), found that of the published 10 studies of PJAC radiological and clinical outcomes included in their systematic review, PJAC demonstrated promising functional outcomes, with MRIs demonstrating some filling of the OLTs.⁵² However, there was some disparity in cartilage repair between studies and a consistent lack of repair in the subchondral bone and subchondral lamina.⁵² Furthermore, a comparative study found PJAC had no advantage over microfracture based on patient reported outcomes.⁵³

Cell-based surgical interventions are regenerative medicine methods used to biologically regenerate the cartilage rather than replace it. Techniques include autologous chondrocyte implantation (ACI), autologous matrix-induced chondrogenesis (AMIC), platelet-rich plasma (PRP) and bone-marrow aspirate concentrate (BMAC). These treatment modalities are often used following a failed microfracture.⁵⁴ ACI is a long-established 2-stage procedure initially developed for chondral/osteochondral lesions in the knee,⁵⁵ that, in the ankle, involves harvesting macroscopically normal hyaline cartilage either from the anterior talus or detached osteochondral fragments.^{56,57} Previously, harvests for ankle ACI have been obtained from the knee, with limited donor-site morbidity.^{58,59} Chondrocytes are enzymatically extracted from the cartilage and culture-expanded *in vitro* prior to being re-implanted into the defect some 3–4 weeks later, beneath either a periosteal patch or a commercially available type I/III collagen patch.⁶⁰ Alternatively, extracted chondrocytes can be cultured directly on the collagen patch, a procedure known as matrix-assisted ACI, or MACI. Pagliuzzi et al. (2018) demonstrated a significant improvement in the patient AOFAS score at 7 years (87.2 ± 14.5 months) following the ACI.⁶¹ Despite the recent technical appraisal by the National Institute for Clinical Excellence (NICE) approving the use of ACI in the knee,⁶² the same cannot be said for the ankle. Current guidelines state that ACI will not be routinely commissioned due to lack of evidence of the clinical effectiveness of this therapy in the ankle, so it remains a clinical trial/efficacy study line of treatment only at present (within the UK at least).

To eradicate the need for a 2-stage procedure, the AMIC technique offers a promising, cost-effective alternative that was originally developed for the treatment of defects in the knee.⁶³ The technique consists of performing a microfracture followed by securing a commercially available type I/III collagen patch over the defect with the aim of not only trapping any MSCs entering the defect area through the bleeding process, but also providing a scaffold on which the cells may adhere and proliferate.⁶⁴ It has been suggested that transforming growth factor beta (TGF-beta) present in the fibrin glue used to adhere the patch may enhance MSC chondrogenic differentiation.⁶⁵ However, a recent systematic review of AMIC in the talus concluded that more clinical studies are

required to validate the efficacy and safety of this technique.⁶⁶ Complete defect filling was demonstrated in 88% of patients (n = 33) treated with AMIC when assessed by MRI, along with reduction in pain and improvement in function at 4.7 (mean; range, 2.3–8.0) years post-operatively.⁶⁷ A systematic review of 13 papers, further confirmed the efficacy of AMIC,⁶⁶ as did another of 15 studies with outcomes up to five years post-operatively.⁶⁸

There has been increasing interest in recent years with regards to a biological therapy for OLTs utilising PRP, either autologous or allogenic, which can either be administered directly to the lesion or via intra-articular injection.^{69,70} PRP is rich in various growth factors and cytokines such as TGF-beta, platelet-derived growth factor (PDGF), insulin-like growth factor (IGF) I and II, fibroblast growth factor (FGF) and vascular endothelial growth factor (VEGF) which are believed to enhance the natural healing response by promoting MSC differentiation and cartilage formation.^{71–73} The use of PRP to treat OLTs has also been systematically reviewed and was concluded to result in significantly reduced pain and improved function in comparison with microfracture alone.⁷³ Despite being a promising treatment option, to date, there is limited clinical evidence for the use of PRP and an absence of a standardised preparation technique prior to application.⁷⁴

BMAC is a type of biological adjuvant used for one-step cartilage repair of OLTs, in the most recent decade.⁷⁵ BMAC consists of different types of stem cells and progenitor cells such as MSCs and haematopoietic progenitor cells (HPCs), which have the potential to repair injured hyaline cartilage. BMAC also contains an abundance of growth factors and cytokines which may contribute to the cartilage regeneration process.⁷⁶ In BMAC therapy, bone marrow aspirate is collected from the patient's iliac crest, the white cells in the marrow including MSCs, HPCs and all other immune cell fractions are concentrated with the aid of commercial kits, and injected directly into the patient's OLT, combined with a biological scaffold, such as a hyaluronic acid and fibrin gel.⁷⁷ Unlike the two-stage procedure of ACI, BMAC therapy can be achieved during a single surgical operation, and does not require *in vitro* cell culture, which significantly lowers the financial burden (as BMAC is not considered an advanced therapy medicinal product by regulators), and avoids the heterogeneity caused by inconsistent cell culture protocols between laboratories. However, BMAC therapy still lacks standardisation; there is no defined protocol for bone marrow aspirate collection and concentration, and the scaffolds used in the treatment vary.

BMAC has been demonstrated to have good long-term results in the treatment of both OLTs and OA.^{77–79} In one of these studies patients receiving BMAC therapy demonstrated significantly increased AOFAS scores, decreased Ankle Osteoarthritis Scale (AOS) pain and disability subscales and high patient satisfaction after 24 months and 10 year follow-up.⁷⁷ Interestingly, two studies both reported that the AOFAS score increased greatly in the first 24 months post-operatively, but after 48 months the AOFAS score was slightly decreased, yet remained significantly higher than the pre-operative score.^{77,78} The reason behind this still needs further investigation.

5. Conclusion

In conclusion, there are several conservative and surgical approaches currently used to treat OLTs. All of these procedures have pros- and cons- and a decision has to be made based upon the likely efficacy compared with the potential risks e.g. donor site morbidity or risks associated with multiple surgical procedures. The judgement of which approach is most suited to each patient depends on the specific presentation of the defect e.g. size, site (contained or uncontained) depth and cyst presence. Moreover, for certain

demographics of patient there will be greater impetus on choosing an approach which will allow for rapid return to normal physical activity, such as athletes. There remains a need to better predict which procedure is most likely to benefit an individual, perhaps through the use of imaging or fluid biomarkers, to ensure that repair of OLTs can be achieved as quickly as possible preventing further damage to the joint and the likelihood of developing OA.

Funding

The authors would like to acknowledge Versus Arthritis (Grants 18480, 19429, 21156 and 20815), the Medical Research Council (MR/L010453/1, MR/N02706X/1 and MR/S015167/1) and the Orthopaedic Institute Ltd (RPG 184) for supporting the salaries of the authors (TL, HM, CH and KW) and associated research.

Declarations of competing interest

None.

References

1. Steele JR, Dekker TJ, Federer AE, Liles JL, Adams SB, Easley ME. Osteochondral lesions of the talus: current concepts in diagnosis and treatment. *Foot Ankle Orthopaedics*. 2018;3(3). <https://doi.org/10.1177/2473011418779559>, 2473011418779559.
2. Shimozone Y, Yasui Y, Ross AW, Kennedy JG. Osteochondral lesions of the talus in the athlete: up to date review. *Curr Rev Musculoskelet Med*. 2017;10(1): 131–140. <https://doi.org/10.1007/s12178-017-9393-8>.
3. Looze CA, Capo J, Ryan MK, et al. Evaluation and management of osteochondral lesions of the talus. *Cartilage*. 2017;8(1):19–30. <https://doi.org/10.1177/1947603516670708>.
4. Verhagen RAW, Struijs PAA, Bossuyt PMM, van Dijk CN. Systematic review of treatment strategies for osteochondral defects of the talar dome. *Foot Ankle Clin*. 2003;8(2):233–242. [https://doi.org/10.1016/S1083-7515\(02\)00064-5](https://doi.org/10.1016/S1083-7515(02)00064-5).
5. Canale ST, Belding RH. Osteochondral lesions of the talus. *J Bone Joint Surg Am*. 1980;62(1):97–102.
6. Hurley ET, Stewart SK, Kennedy JG, Strauss EJ, Calder J, Ramasamy A. Current management strategies for osteochondral lesions of the talus. *Bone Joint J*. 2021;103-B(2):207–212. <https://doi.org/10.1302/0301-620X.103B2.BJJ-2020-1167.R1>.
7. Stufkens SA, Knupp M, Horisberger M, Lampert C, Hintermann B. Cartilage lesions and the development of osteoarthritis after internal fixation of ankle fractures: a prospective study. *JBJS*. 2010;92(2):279–286. <https://doi.org/10.2106/JBJS.H.01635>.
8. Irwin RM, Shimozone Y, Yasui Y, McGill R, Deyer TW, Kennedy JG. Incidence of coexisting talar and tibial osteochondral lesions correlates with patient Age and lesion location. *Orthopaedic J. Sports Med*. 2018;6(8). <https://doi.org/10.1177/2325967118790965>, 2325967118790965.
9. Cunningham DJ, Adams SB. Arthroscopic treatment of osteochondral lesions of the talus with microfracture and platelet-rich plasma-infused microneedled cartilage allograft. *Arthroscopy Techniq*. 2020;9(5):e627–e637. <https://doi.org/10.1016/j.eats.2020.01.012>.
10. Orr JD, Dawson LK, Garcia EJ, Kirk KL. Incidence of osteochondral lesions of the talus in the United States military. *Foot Ankle Int*. 2011;32(10):948–954. <https://doi.org/10.3113/FAI.2011.0948>.
11. Murawski CD, Kennedy JG. Operative treatment of osteochondral lesions of the talus. *J Bone Joint Surg Am*. 2013;95(11):1045–1054. <https://doi.org/10.2106/JBJS.L.00773>.
12. Tol JL, Struijs PAA, Bossuyt PMM, Verhagen RAW, van Dijk CN. Treatment strategies in osteochondral defects of the talar dome: a systematic review. *Foot Ankle Int*. 2000;21(2):119–126. <https://doi.org/10.1177/107110070002100205>.
13. Berndt AL, Harty M. Transchondral fractures (osteochondritis dissecans) of the talus. *JBJS*. 1959;41(7):1363.
14. O'Loughlin PF, Heyworth BE, Kennedy JG. Current concepts in the diagnosis and treatment of osteochondral lesions of the ankle. *Am J Sports Med*. 2010;38(2): 392–404. <https://doi.org/10.1177/0363546509336336>.
15. Raikin SM, Elias I, Zoga AC, Morrison WB, Besser MP, Schweitzer ME. Osteochondral lesions of the talus: localization and morphologic data from 424 patients using a novel anatomical grid scheme. *Foot Ankle Int*. 2007;28(2): 154–161. <https://doi.org/10.3113/FAI.2007.0154>.
16. Orr JD, Dutton JR, Fowler JT. Anatomic location and morphology of symptomatic, operatively treated osteochondral lesions of the talus. *Foot Ankle Int*. 2012;33(12):1051–1057. <https://doi.org/10.3113/FAI.2012.1051>.
17. Millington SA, Grabner M, Wozelka R, Anderson DD, Hurwitz SR, Crandall JR. Quantification of ankle articular cartilage topography and thickness using a high resolution stereophotography system. *Osteoarthritis Cartilage*. 2007;15(2): 205–211. <https://doi.org/10.1016/j.joca.2006.07.008>.

18. Henak CR, Ross KA, Bonnevie ED, et al. Human talar and femoral cartilage have distinct mechanical properties near the articular surface. *J Biomech.* 2016;49(14):3320–3327. <https://doi.org/10.1016/j.jbiomech.2016.08.016>.
19. Wan L, de Asla RJ, Rubash HE, Li G. In vivo cartilage contact deformation of human ankle joints under full body weight. *J Orthop Res.* 2008;26(8):1081–1089. <https://doi.org/10.1002/jor.20593>.
20. Sugimoto K, Takakura Y, Tohno Y, Kumai T, Kawate K, Kadono K. Cartilage thickness of the talar dome. *Arthrosc J Arthrosc Relat Surg.* 2005;21(4):401–404. <https://doi.org/10.1016/j.arthro.2004.12.005>.
21. Cher WL, Utturkar GM, Spritzer CE, Nunley JA, DeFrate LE, Collins AT. An analysis of changes in vivo cartilage thickness of the healthy ankle following dynamic activity. *J Biomech.* 2016;49(13):3026–3030. <https://doi.org/10.1016/j.jbiomech.2016.05.030>.
22. Treppo S, Koepp H, Quan EC, Cole AA, Kuettner KE, Grodzinsky AJ. Comparison of biomechanical and biochemical properties of cartilage from human knee and ankle pairs. *J Orthop Res.* 2000;18(5):739–748. <https://doi.org/10.1002/jor.1100180510>.
23. Kraeutler MJ, Kaenkumchorn T, Pascual-Garrido C, Wimmer MA, Chubinskaya S. Peculiarities in ankle cartilage. *Cartilage.* 2017;8(1):12–18. <https://doi.org/10.1177/1947603516642572>.
24. Delco ML, Kennedy JG, Bonassar LJ, Fortier LA. Post-traumatic osteoarthritis of the ankle: a distinct clinical entity requiring new research approaches. *J Orthop Res.* 2017;35(3):440–453. <https://doi.org/10.1002/jor.23462>.
25. Valderrabano V, Horisberger M, Russell I, Dougall H, Hintermann B. Etiology of ankle osteoarthritis. *Clin Orthop Relat Res.* 2008;467(7):1800. <https://doi.org/10.1007/s11999-008-0543-6>.
26. Bauer M, Jonsson K, Linden B. Osteochondritis dissecans of the ankle. A 20-year follow-up study. *J Bone Joint Surg Br.* 1987;69-B(1):93–96. <https://doi.org/10.1302/0301-620X.69B1.3818743>.
27. Gunther KP, Sturmer T, Sauerland S, et al. Prevalence of generalised osteoarthritis in patients with advanced hip and knee osteoarthritis: the Ulm Osteoarthritis Study. *Ann Rheum Dis.* 1998;57(12):717–723. <https://doi.org/10.1136/ard.57.12.717>.
28. Muehleman C, Margulis A, Bae WC, Masuda K. Relationship between knee and ankle degeneration in a population of organ donors. *BMC Med.* 2010;8:48. <https://doi.org/10.1186/1741-7015-8-48>.
29. Rungprai C, Tennant JN, Gentry RD, Phisitkul P. Management of osteochondral lesions of the talar dome. *Open Orthop J.* 2017;11:743–761. <https://doi.org/10.2174/1874325001711010743>.
30. McGahan PJ, Pinney SJ. Current concept review: osteochondral lesions of the talus. *Foot Ankle Int.* 2010;31(1):90–101. <https://doi.org/10.3113/FAI.2010.0090>.
31. Verhagen RaW, Maas M, Dijkgraaf MGW, Tol JL, Krips R, van Dijk CN. Prospective study on diagnostic strategies in osteochondral lesions of the talus. *J Bone Joint Surg Br.* 2005;87-B(1):41–46. <https://doi.org/10.1302/0301-620X.87B1.14702>.
32. Schuman L, Struijs PaA, van Dijk CN. Arthroscopic treatment for osteochondral defects of the talus. *J Bone Joint Surg Br.* 2002;84-B(3):364–368. <https://doi.org/10.1302/0301-620X.84B3.0840364>.
33. Easley ME, Latt LD, Santangelo JR, Merian-Genest M, Nunley 2nd JA. Osteochondral lesions of the talus: long-term results. *Orthop Trans.* 2010;18(10):616–630. <https://doi.org/10.5435/00124635-201010000-00005>.
34. Hepple S, Winson IG, Glew D. Osteochondral lesions of the talus: a revised classification. *Foot Ankle Int.* 1999;20(12):789–793. <https://doi.org/10.1177/107110079902001206>.
35. Zinman C, Wolfson N, Reis ND. Osteochondritis dissecans of the dome of the talus. Computed tomography scanning in diagnosis and follow-up. *J Bone Jt Surg Am Vol.* 1988;70(7):1017–1019.
36. Ferkel RD, Sgaglione NA, DelPizzo W. Arthroscopic treatment of osteochondral lesions of the talus: long-term results. *Orthop Trans.* 1990;14:172–173.
37. Brittberg M, Winalski CS. Evaluation of cartilage injuries and repair. *J Bone Joint Surg Am.* 2003;85-(A Suppl 2):58–69. <https://doi.org/10.2106/00004623-200300002-00008>.
38. Cheng MS, Ferkel RD, Applegate GR. Osteochondral lesions of the talus: a radiologic and surgical comparison. In: *Annual Meeting of the Academy of Orthopaedic Surgeons.* New Orleans.; 1995:16–21.
39. Zengerink M, Struijs PAA, Tol JL, van Dijk CN. Treatment of osteochondral lesions of the talus: a systematic review. *Knee Surg Sports Traumatol Arthrosc.* 2010;18(2):238–246. <https://doi.org/10.1007/s00167-009-0942-6>.
40. Smith GD, Knutsen G, Richardson JB. A clinical review of cartilage repair techniques. *J Bone Joint Surg Br.* 2005;87-B(4):445–449. <https://doi.org/10.1302/0301-620X.87B4.15971>.
41. Kim TY, Song SH, Baek JH, Hwang YG, Jeong BO. Analysis of the changes in the clinical outcomes according to time after arthroscopic microfracture of osteochondral lesions of the talus. *Foot Ankle Int.* 2019;40(1):74–79. <https://doi.org/10.1177/1071100718794944>.
42. Choi S-W, Lee G-W, Lee K-B. Arthroscopic microfracture for osteochondral lesions of the talus: functional outcomes at a mean of 6.7 Years in 165 consecutive ankles. *Am J Sports Med.* 2020;48(1):153–158. <https://doi.org/10.1177/0363546519887957>.
43. Chuckyaiwong B, Berkson EM, Theodore GH. Microfracture for osteochondral lesions of the ankle: outcome analysis and outcome predictors of 105 cases. *Arthrosc J Arthrosc Relat Surg.* 2008;24(1):106–112. <https://doi.org/10.1016/j.arthro.2007.07.022>.
44. Dahmen J, Hurley ET, Shimozone Y, et al. Evidence-based Treatment of Failed Primary Osteochondral Lesions of the Talus: A Systematic Review on Clinical Outcomes of Bone Marrow Stimulation. *CARTILAGE*; 2021. <https://doi.org/10.1177/1947603521996023>. Published online February 22, 1947603521996023.
45. Lomax A, Calder J. Retrograde drilling for the treatment of osteochondral lesions in the ankle. In: Randelli P, Dejour D, van Dijk CN, Denti M, Seil R, eds. *Arthroscopy: Basic to Advanced.* Springer; 2016:1023–1031. https://doi.org/10.1007/978-3-662-49376-2_85.
46. Hangody L, Füles P. Autologous osteochondral mosaicplasty for the treatment of full-thickness defects of weight-bearing joints: ten years of experimental and clinical experience. *JBS.* 2003;85(suppl 2):25–32.
47. Hangody L, Kish G, Módis L, et al. Mosaicplasty for the treatment of osteochondritis dissecans of the talus: two to seven year results in 36 patients. *Foot Ankle Int.* 2001;22(7):552–558. <https://doi.org/10.1177/107110070102200704>.
48. Pereira GF, Steele JR, Fletcher AN, Clement RD, Arasa MA, Adams SB. Fresh osteochondral allograft transplantation for osteochondral lesions of the talus: a systematic review. *J Foot Ankle Surg.* Published online February 9, 2021. doi: 10.1053/j.jfas.2021.02.001.
49. Shimozone Y, Hurley ET, Myerson CL, Kennedy JG. Good clinical and functional outcomes at mid-term following autologous osteochondral transplantation for osteochondral lesions of the talus. *Knee Surg Sports Traumatol Arthrosc.* 2018;26(10):3055–3062. <https://doi.org/10.1007/s00167-018-4917-3>.
50. Giza E, Delman C, Coetzee JC, Schon LC. Arthroscopic treatment of talus osteochondral lesions with particulated juvenile allograft cartilage. *Foot Ankle Int.* 2014;35(10):1087–1094. <https://doi.org/10.1177/1071100714548704>.
51. Andrade R, Vasta S, Pereira R, et al. Knee donor-site morbidity after mosaicplasty – a systematic review. *J. Exp. Ortop.* 2016;3(1):31. <https://doi.org/10.1186/s40634-016-0066-0>.
52. Aldawsari K, Alrabai HM, Sayed A, Alrashidi Y. Role of particulated juvenile cartilage allograft transplantation in osteochondral lesions of the talus: a systematic review. *Foot Ankle Surg.* 2021;27(1):10–14. <https://doi.org/10.1016/j.fas.2020.02.011>.
53. Karnovsky SC, DeSandis B, Haleem AM, Sofka CM, O'Malley M, Drakos MC. Comparison of juvenile allogeneous articular cartilage and bone marrow aspirate concentrate versus microfracture with and without bone marrow aspirate concentrate in arthroscopic treatment of talar osteochondral lesions. *Foot Ankle Int.* 2018;39(4):393–405. <https://doi.org/10.1177/1071100717746627>.
54. Lambers KTA, Dahmen J, Reilingh ML, van Bergen CJA, Stufkens SAS, Kerkhoffs GMMJ. No superior surgical treatment for secondary osteochondral defects of the talus. *Knee Surg Sports Traumatol Arthrosc.* 2018;26(7):2158–2170. <https://doi.org/10.1007/s00167-017-4629-0>.
55. Brittberg M, Lindahl A, Nilsson A, Ohlsson C, Isaksson O, Peterson L. Treatment of deep cartilage defects in the knee with autologous chondrocyte transplantation. *N Engl J Med.* 1994;331(14):889–895. <https://doi.org/10.1056/NEJM199410063311401>.
56. Johnson B, Lever C, Roberts S, et al. Cell cultured chondrocyte implantation and scaffold techniques for osteochondral talar lesions. *Foot Ankle Clin.* 2013;18(1):135–150. <https://doi.org/10.1016/j.fcl.2012.12.008>.
57. Giannini S, Buda R, Grigolo B, Vannini F, De Franceschi L, Facchini A. The detached osteochondral fragment as a source of cells for autologous chondrocyte implantation (ACI) in the ankle joint. *Osteoarthritis Cartilage.* 2005;13(7):601–607. <https://doi.org/10.1016/j.joca.2005.02.010>.
58. McCarthy HS, Richardson JB, Parker JCE, Roberts S. Evaluating joint morbidity after chondral harvest for autologous chondrocyte implantation (ACI): a study of ACI-treated ankles and hips with a knee chondral harvest. *CARTILAGE.* 2016;7(1):7–15. <https://doi.org/10.1177/1947603515607963>.
59. Whittaker J-P, Smith G, Makwana N, et al. Early results of autologous chondrocyte implantation in the talus. *J. Bone Joint Surg. Br.* 2005;87-B(2):179–183. <https://doi.org/10.1302/0301-620X.87B2.15376>.
60. López-Alcorocho JM, Guillén-Vicente I, Rodríguez-Iñigo E, et al. High-density autologous chondrocyte implantation as treatment for ankle osteochondral defects. *Cartilage.* 2019. <https://doi.org/10.1177/1947603519835898>. Published online March 17, 1947603519835898.
61. Pagliuzzi G, Vannini F, Battaglia M, Ramponi L, Buda R. Autologous chondrocyte implantation for talar osteochondral lesions: comparison between 5-year follow-up magnetic resonance imaging findings and 7-year follow-up clinical results. *J Foot Ankle Surg.* 2018;57(2):221–225. <https://doi.org/10.1053/j.jfas.2017.05.013>.
62. National Institute of Health and Care Excellence (NICE). *Autologous Chondrocyte Implantation for Treating Symptomatic Articular Cartilage Defects of the Knee, Technology Appraisal Guidance [TA477]*; 2017. Published <https://www.nice.org.uk/guidance/ta477>. Accessed March 18, 2021.
63. Benthien JP, Behrens P. The treatment of chondral and osteochondral defects of the knee with autologous matrix-induced chondrogenesis (AMIC): method description and recent developments. *Knee Surg Sports Traumatol Arthrosc.* 2011;19(8):1316–1319. <https://doi.org/10.1007/s00167-010-1356-1>.
64. Benthien JP, Behrens P. Autologous matrix-induced chondrogenesis (AMIC): combining microfracturing and a collagen I/III matrix for articular cartilage resurfacing. *Cartilage.* 2010;1(1):65–68. <https://doi.org/10.1177/1947603509360044>.
65. Gille J, Meisner U, Ehlers EM, Müller A, Russlies M, Behrens P. Migration pattern, morphology and viability of cells suspended in or sealed with fibrin glue: a histomorphologic study. *Tissue Cell.* 2005;37(5):339–348. <https://doi.org/10.1016/j.tice.2005.05.004>.
66. Malahias M-A, Kostretzis L, Megaloikonomos PD, et al. Autologous matrix-

- induced chondrogenesis for the treatment of osteochondral lesions of the talus: a systematic review. *Orthop Rev.* 2021;12(4). <https://doi.org/10.4081/or.2020.8872>.
67. Weigelt L, Hartmann R, Pfirrmann C, Espinosa N, Wirth SH. Autologous matrix-induced chondrogenesis for osteochondral lesions of the talus: a clinical and radiological 2- to 8-year follow-up study. *Am J Sports Med.* 2019;47(7):1679–1686. <https://doi.org/10.1177/0363546519841574>.
 68. Walther M, Valderrabano V, Wiewiorski M, et al. Is there clinical evidence to support autologous matrix-induced chondrogenesis (AMIC) for chondral defects in the talus? A systematic review and meta-analysis. *Foot Ankle Surg.* Published online August 16, 2020. doi:10.1016/j.fas.2020.07.011.
 69. Guney A, Akar M, Karaman I, Oner M, Guney B. Clinical outcomes of platelet rich plasma (PRP) as an adjunct to microfracture surgery in osteochondral lesions of the talus. *Knee Surg Sports Traumatol Arthrosc.* 2015;23(8):2384–2389. <https://doi.org/10.1007/s00167-013-2784-5>.
 70. Mei-Dan O, Carmont MR, Laver L, Mann G, Maffulli N, Nyska M. Platelet-rich plasma or hyaluronate in the management of osteochondral lesions of the talus. *Am J Sports Med.* 2012;40(3):534–541. <https://doi.org/10.1177/0363546511431238>.
 71. Sun Y, Feng Y, Zhang CQ, Chen SB, Cheng XG. The regenerative effect of platelet-rich plasma on healing in large osteochondral defects. *Int Orthop.* 2010;34(4):589–597. <https://doi.org/10.1007/s00264-009-0793-2>.
 72. Xie X, Zhang C, Tuan RS. Biology of platelet-rich plasma and its clinical application in cartilage repair. *Arthritis Res Ther.* 2014;16(1):204. <https://doi.org/10.1186/ar4493>.
 73. Yausep OE, Madhi I, Trigkilidas D. Platelet rich plasma for treatment of osteochondral lesions of the talus: a systematic review of clinical trials. *J Orthop.* 2020;18:218–225. <https://doi.org/10.1016/j.jor.2020.01.046>.
 74. Henning PR, Grear BJ. Platelet-rich plasma in the foot and ankle. *Curr Rev Musculoskelet Med.* 2018;11(4):616–623. <https://doi.org/10.1007/s12178-018-9522-z>.
 75. Kennedy JG, Murawski CD. The treatment of osteochondral lesions of the talus with autologous osteochondral transplantation and bone marrow aspirate concentrate: surgical technique. *Cartilage.* 2011;2(4):327–336. <https://doi.org/10.1177/1947603511400726>.
 76. Holton J, Imam M, Ward J, Snow M. The basic science of bone marrow aspirate concentrate in chondral injuries. *Orthop Rev.* 2016;8(3). <https://doi.org/10.4081/or.2016.6659>.
 77. Vannini F, Filardo G, Altamura SA, et al. Bone marrow aspirate concentrate and scaffold for osteochondral lesions of the talus in ankle osteoarthritis: satisfactory clinical outcome at 10 years. *Knee Surg Sports Traumatol Arthrosc.* 2021. <https://doi.org/10.1007/s00167-021-06494-y>. Published online February 19.
 78. Giannini S, Buda R, Battaglia M, et al. One-step repair in talar osteochondral lesions: 4-year clinical results and T2-mapping capability in outcome prediction. *Am J Sports Med.* 2013;41(3):511–518. <https://doi.org/10.1177/0363546512467622>.
 79. Hannon CP, Ross KA, Murawski CD, et al. Arthroscopic bone marrow stimulation and concentrated bone marrow aspirate for osteochondral lesions of the talus: a case-control study of functional and magnetic resonance observation of cartilage repair tissue outcomes. *Arthrosc J Arthrosc Relat Surg.* 2016;32(2):339–347. <https://doi.org/10.1016/j.arthro.2015.07.012>.