

1 Hand osteoarthritis: clinical phenotypes, molecular mechanisms and disease management

2

3 Michelle Marshall¹, Fiona E. Watt², Tonia L. Vincent², Krysia Dziedzic^{1*}

4

5 ¹ Research Institute for Primary Care and Health Sciences, Arthritis Research UK Primary Care Centre, David
6 Weatherall Building, Keele University, United Kingdom.7 ² Arthritis Research UK Centre for OA Pathogenesis, Kennedy Institute of Rheumatology, University of
8 Oxford, Nuffield Department of Orthopaedics, Oxford, United Kingdom.

9

10 *email: k.s.dziedzic@keele.ac.uk

11

12 Abstract

13 Osteoarthritis (OA) is a highly prevalent condition and the hand is the most commonly affected site.

14 Patients with hand OA frequently report symptoms of pain, functional limitations, and frustration in

15 undertaking everyday activities. The condition presents clinically with changes to the bone, ligaments,

16 cartilage and synovial tissue, which can be observed using radiography, ultrasonography or MRI. Hand OA is

17 a heterogeneous disorder and is considered to be multifactorial in aetiology. This review provides an

18 overview of the epidemiology, presentation and burden of hand OA, including an update on hand OA

19 imaging (including the development of novel techniques), disease mechanisms and management. In

20 particular, areas for which new evidence has substantially changed the way we understand, consider and

21 treat hand OA are highlighted. For example, genetic studies, clinical trials and careful prospective imaging

22 studies from the past 5 years are beginning to provide insights into the pathogenesis of hand OA that might

23 uncover new therapeutic targets in disease.

24

25

1 [H1] Introduction

2 Osteoarthritis (OA) is one of the leading causes of disability worldwide¹. With the average age of
3 populations increasing, the impact of OA and joint pain is set to rise². Disabling hand pain is a common
4 complaint, affecting ~12% of individuals aged over 50 years in the UK general population³. For many of
5 these individuals, this symptom can be ascribed to hand OA, which is the most common form of OA. Hand
6 OA is a heterogeneous condition, often involving multiple joints⁴, and can have distinct (but sometimes
7 overlapping) patterns of joint involvement: for example, OA of the interphalangeal joints (IPJ) and/or the
8 first carpometacarpal joint (CMCJ)⁵.

9
10 A gap exists between guidelines for the management of hand OA and current standards of treatment⁶.

11 Healthcare initiatives such as JIGSAW-E (Joint Implementation of Guidelines for oSteoArthritis in Western
12 Europe; funded by EIT-Health) aim to close the evidence–practice gap for OA⁷ by implementing
13 international guidelines and quality standards^{8,9}. A common misconception is that OA of the hands effects
14 the quality of life of individuals less than OA of the lower limbs, and many patients are encouraged to
15 believe that hand OA is an inevitable result of ageing and that nothing can be done to improve the disease
16 symptoms¹⁰. These unfounded assumptions make prioritizing healthcare for hand OA a challenge.

17
18 In this review, we provide an overview of the epidemiology, presentation and burden of hand OA and
19 present areas where in the past 5 years new evidence has substantially changed the way we understand,
20 consider and treat hand OA. We include updates on the imaging of hand OA and the development of novel
21 imaging techniques, advances in knowledge of disease mechanisms, and the management of hand OA.

22 23 [H1] Epidemiology

24 [H2] Definitions of hand OA

25 Hand OA can be defined in a number of ways: by the ACR clinical criteria²¹¹, by structural changes
26 determined by imaging (most frequently using plain radiography; so-called radiographic hand OA) and by
27 radiographic changes accompanied by the presence of typical symptoms (pain, aching or stiffness; referred

1 to as symptomatic hand OA). For the latter two categories, a range of different definitions, particularly
2 radiographic definitions^{Marshall 2008}, have been used in the study of hand OA (Box 1).

3
4 Radiographically, hand OA is characterized, as with other forms of OA, by joint space narrowing (JSN),
5 osteophyte formation (which, for any joint, is pathognomonic of radiographic OA), subchondral sclerosis
6 and subchondral cyst formation. Researchers have attempted to improve the detection of early disease
7 features (including features that might not be evident by plain radiograph) by using MRI or
8 ultrasonography; however, these techniques have not found a place in the diagnosis of hand OA in the
9 clinic to date¹².

10

11 [H2] Prevalence

12 Hand OA is a highly prevalent condition with a well-recognized female preponderance that is particularly
13 notable in patients with severe symptomatic disease presenting to secondary care^{13,14}. Estimates of the
14 prevalence of hand OA vary depending on the definition of hand OA used, as well as the age, sex and
15 geographical area of the population studied, and can also be influenced by genetic factors, occupation and
16 diet. Of the various hand OA definitions, radiographic hand OA is associated with the highest prevalence,
17 ranging from 21% in a US population to 92% in a Japanese population^{15,16,17}. By contrast, the prevalence of
18 symptomatic hand OA is much lower than radiographic hand OA, ranging from 3% in Iranian and Chinese
19 populations to 16% in a US population^{18,19,20}. Prevalence estimates for hand OA are generally higher than
20 those reported for hip and knee OA (hip OA: radiographic 1.0–45.0%, symptomatic 0.9–7.4%; knee OA:
21 radiographic 7.1–70.8%, symptomatic 5.4–24.2%)¹⁵. The prevalence of hand OA is also higher in some
22 groups of individuals, such as in patients with a HIV-1 infection, than in the general population²¹.

23

24 [H2] Incidence and progression

25 The distinction between incidence (occurrence of the disease) and progression (development towards a
26 more advanced stage of the disease) of hand OA is somewhat arbitrary and depends on the case definition
27 of the disease used. With this caveat in mind, in one study of a USA population, the lifetime risk of

1 developing symptomatic hand OA in at least one hand by the age of 85 years was estimated at 40%, with
2 47% of women and 25% of men developing the disease in this population²². The annual incidence of hand
3 OA varies between 0.2% and 4.7% for radiographic hand OA, and 0.1% and 1.1% for symptomatic hand OA
4 irrespective of age, sex and geographical location^{23, 24, 25} (Table 1). The incidence of hand OA peaks at the
5 age of 50 in women and greatly exceeds the incidence measured for men at that age²⁶. Progression of hand
6 OA is usually slow, and only a small number of hand joints exhibit changes in each patient²⁴. The rates of
7 radiographic progression vary from 3.2% to 23.5% per year depending on the population studied, the
8 grading scale used and whether the definition of progression also incorporates incident OA (that is, new
9 onset OA) (Table 2)^{27,23}.

10

11 **[H1] Disease presentation and burden**

12 [H2] Signs and symptoms

13 OA is considered a condition of the whole joint, rather than just the articular cartilage, and signs and
14 symptoms can arise from the cartilage, underlying bone, synovium, muscles, tendons and ligaments (or the
15 sites of ligament insertion into the bone)^{29,30}. Symptoms commonly include pain, stiffness and limitation or
16 restriction of movement such as a decrease of grip and/or pinch strength. Signs of hand OA include 'nodes'
17 of the affected IPJs (firm swellings over the superolateral and dorsal aspects of the distal interphalangeal
18 joints (DIPJ) and proximal interphalangeal joints (PIPJ), known as Heberden and Bouchard nodes,
19 respectively) and deformities such as squaring of the thumb base (Figure 1). Inflammation can produce
20 redness, warmth, effusion and/or soft tissue swelling.

21

22 Individuals with hand OA can be divided into different subgroups depending on the joints in the hands that
23 are affected; these subgroups consist of nodal OA, first CMJ OA and another presentation called erosive
24 hand OA, in which the subchondral bone is affected by central erosions. First CMJ OA is thought to occur
25 most frequently, followed by nodal IPJ OA, a non-nodal form of IPJ OA and erosive hand OA⁵. However,
26 apart from first CMJ OA, which frequently occurs in isolation, there is considerable overlap in
27 presentations among these subgroups, suggesting shared aetiologies⁵.

1

2 [H3] First CMCJ OA

3 Patients with first CMCJ OA have increased pain sensitivity, a reduced range of motion in thumb abduction
4 and a decreased combined thumb abduction and index finger extension strength compared with healthy
5 individuals³¹. Notable associations between self-reported pain and function have been reported for these
6 patients. Furthermore, compared with healthy individuals, patients with this condition have reduced grip
7 and pinch strength³², including a decrease in cylindrical grasp and key pinch strength that can begin in the
8 early stages of disease^{33,34}. Some of these presentations might be due to changes in the structure and
9 composition of the joint and changes in the innervation of the dorsal radial ligament, which has an
10 important proprioceptive and stabilising role for the thumb base³⁵. In individuals with symptomatic first
11 CMCJ OA, the presence of both ligament ruptures and dorsal subluxation is a common finding on MRI^{36,37}.
12 The grind test (where the examiner exerts pressure whilst rotating the joint to test whether pain or crepitus
13 are elicited) has frequently been used to determine the presence of first CMCJ OA³⁸. However, in a 2014
14 study, the traction-shift (subluxation-relocation) test (where the examiner provokes subluxation and
15 relocation of the joint passively to test whether pain is elicited) had a higher sensitivity, specificity and
16 positive and negative predictive values for first CMCJ OA than the grind test³⁹.

17

18 [H3] Nodal OA

19 Nodes are the hallmark of nodal OA and most frequently affect the index finger DIPJ (Heberden nodes),
20 followed by the thumb IPJ and the PIPJ (Bouchard nodes). The pattern of joints affected by nodes is similar
21 to the pattern of joints affected by radiographic features⁴⁰ but although the presence of nodes is
22 associated with underlying radiographic OA, IPJ OA can present with tenderness and bony enlargement
23 without nodal involvement⁴¹. Nodal OA occurs more often in women than in men and occurs most often in
24 the dominant hand, suggesting the involvement of mechanical and hormonal factors⁴⁰. Patients with nodal
25 OA frequently have synovitis, osteophytes, cartilage loss, and central and marginal erosions⁴²; aesthetic
26 discomfort is also common⁴³. A strong positive association between the presence of nodes and

1 radiographic OA (in particular the occurrence of JSN) supports the notion that a clinical observation of
2 nodes can be taken as an indication of hand OA without the need for radiographic assessment⁴⁰.

3

4 [H3] Erosive hand OA

5 The predominant features of erosive hand OA are central erosions and collapse of the subchondral bone.

6 The term erosive OA is arguably a misnomer as central erosions are evident in many patients to some

7 degree depending on the imaging modality used^{44,45}; hence, this condition probably represents an extreme

8 phenotype of these changes. Although erosive hand OA is commonly considered a separate disease,

9 increasing evidence suggest that this condition is a severe form of hand OA^{46,42,47}. Erosive hand OA can

10 affect the first CMJ as well as the IPJs, but patients rarely have both erosive OA of the first CMJ and IPJ

11 (most patients have central erosions exclusively in one or the other)⁴⁸. Erosive OA of the IPJ occurs

12 predominantly in women whereas erosive OA of the first CMJ occurs more often in men than in women⁴⁸.

13 Erosive hand OA has a higher clinical burden than non-erosive forms of hand OA and the associated

14 disability might be as severe as that associated with rheumatoid arthritis (RA), depending on the setting

15 ^{49,50}.

16

17 Inflammatory changes, including synovitis and tenosynovitis (determined clinically as soft tissue swelling

18 and by ultrasonography) and effusions and central and marginal erosions (determined by MRI), are

19 frequently observed in patients with either erosive hand OA or nodal OA⁴². The frequency and patterns of

20 joints affected by erosive disease and severe non-erosive forms of hand OA are similar^{46,47}. However,

21 progression of synovitis, joint effusion and radiographic OA occur more frequently in patients with erosive

22 hand OA than in patients with non-erosive forms of hand OA (independently of the amount of synovitis and

23 radiographic structural damage present at baseline)^{51,52}. Furthermore, the findings of a 2016 study

24 indicated that patients with erosive hand OA had a higher level of inflammation (including a higher power

25 Doppler activity, which is an indicator of the level of vascularization) than patients with non-erosive hand

26 OA, suggesting that the inflammatory phenotype might differ in erosive and non-erosive forms of hand OA

27 ⁵². This concept requires further investigation.

1

2 [H2] Individual and societal burden

3 The presence of hand OA frequently affects the ability of an individual to undertake everyday activities ^{53,54}.

4 Symptomatic hand OA is associated with poor self-reported general health, although the strength of this

5 association varies by country and is often partially mediated by impaired physical hand function ⁵⁵. In a

6 number of studies, the presence of hand OA and pain related to hand OA has been associated with

7 atherosclerosis and cardiovascular disease ^{56,57,58,59,60}. This association is analogous to the increased

8 cardiovascular mortality observed in patients with painful OA of the large joints compared with the general

9 population ⁶¹; this increased mortality is assumed to be caused by decreased load-bearing exercises but the

10 association with hand OA suggests the involvement of other factors. Conversely, some data from the past 3

11 years would indicate that individuals with hand OA have a similar risk of all-cause and cardiovascular

12 disease-specific mortality to the general population ^{61,62}.

13

14 Patients with hand OA are frequently dissatisfied with the appearance of their hands, especially patients

15 with Heberden and Bouchard nodes, joint deformity and/or erosive hand OA ⁴³. Aesthetic dissatisfaction

16 has negative effects on the patient symptoms, including increasing the level pain and stiffness and

17 decreasing function of the hand; aesthetic dissatisfaction is also associated with depression, anxiety and

18 negative perceptions by the patients about their illness ^{63,64,43}. Patients with hand OA can have a distorted

19 mental representation of pain in the hand, and normalisation of this distortion by multisensory illusions

20 might offer pain relief ⁶⁵.

21

22 Although much is known about the economic burden of hand OA in terms of the direct costs of some

23 treatments, less is known about the indirect costs of this condition such as loss of productivity ^{66,67,68}. For

24 example, in one study, arthroplasty surgery for first CMCJ OA often resulted in substantial time off work ⁶⁹.

25 Further research is required in this area.

26

27 **[H1] Imaging**

1 [H2] Radiography

2 For decades, radiography has been used to determine the presence and severity of hand OA, and to
3 examine disease progression both in clinical and research settings including in randomised controlled trials
4 (RCTs) ^{70,71}. This technology is widely available, inexpensive and is an acceptable procedure to patients.
5 However, the inability to view non-bony structures (such as the joint capsule, synovium, ligaments and
6 tendons and their enthesal attachment to the bone) using radiography and the insensitivity of this
7 technique in detecting structural pathology limits its utility in both settings compared with other imaging
8 modalities. For these reasons and as hand OA can often be reliably diagnosed on the basis of clinical
9 presentations, EULAR and the National Institute for Health and Care Excellence (NICE) do not recommend
10 imaging for the routine diagnosis of hand OA ^{72,8}, although imaging might be useful in excluding other
11 conditions ^{72,73}. Routine imaging is not recommended for clinical monitoring unless there is an unexpected
12 and rapid change in symptoms or clinical characteristics that suggest an alternative diagnoses such as RA or
13 psoriatic arthritis (PsA ⁷²).

14
15 Radiography still has a place in the research setting; however, which scoring methods to use is still debated
16 and might depend on the objective of the study and the population studied (for example, patients with
17 erosive versus patients with non-erosive forms of hand OA) ^{74,75}. Although radiography might have a low
18 sensitivity in detecting features in early disease, the ability of this technique to detect hand OA progression
19 over five years is similar to that of 1.0 Tesla MRI, although these imaging modalities do not always detect
20 progression in the same joints ²⁸. Given the lower cost of radiography compared with MRI, radiography is
21 the suggested imaging modality of choice in observational studies with a long follow-up period ²⁸.

22

23 [H2] Advances in ultrasonography and MRI

24 In the past 10 years, the use of ultrasonography and MRI for assessing patients with hand OA has increased,
25 providing greater insight into the pathology of the disease and increased evidence that these imaging
26 modalities have a higher sensitivity than radiography in determining the presence of pathological features
27 such as osteophytes, JSN and central erosions ^{76,77,78,79,80,47}. Using ultrasonography and MRI, researchers

1 have shown that inflammatory changes in the synovium and at the enthesis of the hands are a common
2 finding in hand OA ^{81,82,83}. Bone marrow lesions (BMLs) are also detectable in the hands by MRI (consistent
3 with other joints affected by OA ^{83,84}.

4
5 Ultrasonography enables real-time multiplanar imaging at a relatively low cost. With this approach,
6 inflammatory and structural changes can be observed without the use of ionising radiation or the need for
7 a contrast agent; however, this technique is operator-dependent and bony structures such as cysts and
8 BMLs cannot be detected. Several ultrasonography scoring systems for hand OA have been developed for
9 grading pathological features as well as for use in research studies ^{85,86,79}. On the basis of inter-observer and
10 inter-reliability scores, the Outcome Measures in Rheumatology (OMERACT) group has endorsed the
11 scoring of osteophytes using the Mathiessen atlas ^{12,79}. However, although ultrasonography is reliable for
12 determining healthy cartilage or a total loss of cartilage, the use of the ultrasonographic atlas for grading
13 the severity of cartilage pathology is not supported ^{12,79}. Ultrasonography findings have a good concordance
14 with MRI findings ^{87,42}, but the associations between ultrasonography findings and symptoms have differed
15 across various studies ^{88,81,82,89,36}.

16
17 Although MRI is more expensive and takes a longer time to scan patients than other imaging modalities,
18 this imaging modality is important in OA research (including in clinical trials) as it enables the visualisation
19 of all joint structures through different pulse sequences in multiple planes ⁹⁰. The Oslo hand OA MRI scoring
20 system includes assessments of osteophytes, joint space narrowing, central erosions, cysts, BMLs,
21 malalignment, collateral ligament pathology, synovitis, and flexor tenosynovitis in the DIPJ and PIPJ ⁹¹. This
22 scoring system has a good intra-rater and inter-rater reliability, has a good construct validity (in relation to
23 joint tenderness) and has a higher sensitivity in determining the presence of osteophytes and erosions than
24 radiography, computerised tomography (CT) or ultrasonography; however, this approach is time-
25 consuming because of the number of features and sites that require examination ^{91,80,92,93}. In patients with
26 erosive hand OA, , the presence of synovitis and BMLs has been assessed by the Oslo hand OA MRI scoring

1 system and has shown good intra- and inter-rater reliability and is associated with clinical symptoms,
2 demonstrating a good construct validity ⁹⁴.

3

4 The Oslo hand OA MRI scoring system has been refined and the updated version, referred to as the
5 HOAMRIS scoring system, includes measurements of the volume and extent of damage to the joint surface
6 (to enable an improved assessment of central erosions compared with the Oslo hand MRI scoring system),
7 excludes the assessment of collateral ligament pathology and flexor tenosynovitis, and combines the
8 assessments of the proximal and distal joint surfaces (which were graded separately for the Oslo scoring
9 system) for grading central erosions, cysts and BMLs ⁹⁵. The HOAMRIS scoring system has a good inter-
10 reader reliability for cross-sectional readings but has a lower longitudinal reliability, which is thought to be
11 because of the small range of change scores for many of the features. The responsiveness of this scoring
12 system to change (as assessed by the standardised response means) at the patient level (that is, the sum
13 scores for all DIPJ and PIPJ) is good for all assessed features, except for cysts and BMLs ⁹⁶.

14

15 A number of imaging features are associated with disease progression. For example, incident synovitis and
16 BMLs determined on MRI are associated with incident joint tenderness after 5 years ⁹⁷. Baseline MRI-
17 defined synovitis, BMLs and JSN predict radiographic progression in hand OA over 2 and 5 years ^{98,99}.
18 Baseline and persistent ultrasonography features including synovitis, joint effusion and power Doppler
19 ultrasonographic activity in hand joints are associated with radiographic progression in the same joints
20 after 2 and 5 years ^{100,101}.

21

22 Researchers have used ultrasonography to measure the treatment response of individuals with hand OA
23 after intramuscular and intra-articular injections of steroid or other agents ^{102,103,36}. However, understanding
24 how inflammatory features in individual hand joints change over time is important to determine if
25 ultrasound is a valid measure of assessing response to treatment. In a longitudinal study of patients with
26 hand OA, inflammatory features that included synovial thickening, effusion or a power Doppler
27 ultrasonography signal were consistently present in most patients over a 3 month period; however, in

1 individual joints, the inflammatory features changed over time, with persistent inflammatory features
2 found in only 19% of the hand joints¹⁰⁴. Further investigation in other study populations and over different
3 time periods is recommended before ultrasound is used as the primary outcome measure in assessing
4 treatment response in individuals hand joints.

5

6 [H2] Developments in Computerised Tomography

7 CT enables more detailed visualisation of the bone structures than radiography, MRI or ultrasonography
8 (albeit, this approach requires a high dose of ionizing radiation); hence, in the past few years this
9 technology has been used for research purposes in hand OA. By using high-resolution peripheral
10 quantitative computed tomography (HR-pQCT), a technique that is based on CT but is able to achieve
11 higher resolution images over a smaller field of view, researchers could show that new bone formation is
12 more common at the cartilage-bone interface and joint margins in hand OA than in PsA¹⁰⁵. Additionally,
13 disease-associated bone formation is located predominately on the palmar and dorsal sites in hand OA
14 whereas PsA has more widespread involvement, suggesting that different mechanisms of aberrant bone
15 formation occur in these two conditions¹⁰⁵. Findings from 3D CT imaging show that the curvature of the
16 trapezial and first metacarpal articular surface of patients with early CM CJ OA differs from that of younger
17 or older healthy individuals¹⁰⁶. Additionally, using MicroCT (radiographic imaging in 3D on a small scale),
18 researchers have identified differences in the structure and configuration of the trapezium trabecular bone
19 in individuals with and without first CM CJ OA¹⁰⁷. These findings indicate that morphological changes of the
20 bones and joints can occur at the thumb base in hand OA.

21

22 [H2] Novel imaging methods in development

23 Following the advancement of laser technology, a number of optical imaging modalities have been
24 developed that might be applicable to hand OA¹⁰⁸ (Box 2), including diffuse optical tomography (DOT),
25 fluorescence optical imaging (FOI) and optical coherence tomography (OCT) as well as related techniques
26 such as photoacoustic imaging (PAI). These techniques offer low risk (non-ionising radiation) imaging,
27 differentiation between the soft tissues in the hand and fast processing times¹⁰⁸. To date, these techniques

1 have been predominantly used for in vitro and ex vivo applications, whereas their use in vivo, particularly in
2 patients with hand OA, is limited and is still undergoing development and testing¹⁰⁹. The use of systemic
3 contrast agents for some of these applications might limit their use and acceptability to patients.

4 5 [H2] Symptoms and structural pathology

6 Discordance or weak associations between clinical symptoms and radiographic structural changes are
7 frequently reported in OA and hand OA is no exception¹¹⁰. However, it is possible that imaging modalities
8 that are more sensitive than those currently in use could reveal stronger associations. In a 2015 systematic
9 review of various cross-sectional studies, the researchers concluded that MRI-defined BMLs, osteophytes,
10 bone attrition and cysts were not associated with hand pain severity¹¹¹. However, various MRI-defined
11 features (such as moderate or severe synovitis, BMLs, central erosions, cartilage attrition and osteophytes),
12 in addition to various ultrasonography-determined features (such as osteophytes, synovitis and the
13 absence of joint cartilage), have been associated with tenderness in the same joints^{110,92,112}. Furthermore,
14 the cumulative effects of OA in multiple hand joints is associated with more severe hand pain¹¹³, functional
15 limitation⁹² and weaker grip and pinch strength^{114,92,17}. Little is known about the course of symptoms in
16 hand OA over time and how they relate to structural pathology. Inflammation (as determined by
17 ultrasound) has been associated with the progression of radiographic hand OA and the subsequent
18 development of bone erosions^{115,116}; however, further longitudinal research will enable a better
19 understating of the disease processes and could help identify potential targets for treatment.

20 21 **[H1] Disease mechanisms**

22 Studying the pathogenesis of hand OA is difficult: researchers have limited access to diseased tissue, and
23 for tissue that is available, the quantities obtained for molecular analysis are small. Healthy donor tissue (to
24 use as a control) is rarely available, and no animal models of hand OA exist. In addition to the
25 epidemiological and in depth prospective imaging studies detailed above, our understanding of hand OA
26 disease pathways comes from a combination of genetic data analysis, and the outcomes (positive or
27 negative) of clinical studies.

1
2 An important question to address is whether hand OA shares similar pathogenic pathways with OA at other
3 joint sites. Of the common aetiological factors, perhaps the most important factor is abnormal mechanical
4 loading. Although the joints of the hands are not weight-bearing, they are nonetheless load-bearing.
5 Evidence for the involvement of mechanical loading in the development of hand OA is best demonstrated
6 by the higher prevalence of OA in the dominant hand than in the non-dominant hand (80% of right-handed
7 individuals with hand OA are predominately affected in their right hand)¹¹⁷ and the lack of disease in the
8 immobilized hand (for example, owing to hemiparesis or polio) of some patients with OA of the other hand
9^{118,119}. Inflammatory changes in the entheses of the interphalangeal joints of patients with hand OA
10 suggests that this tissue might be an important area of stress¹²⁰. Several features are unique to hand OA.
11 For instance, unlike OA of the large joints, the incidence of hand OA peaks around the time of the
12 menopause²⁶, the early inflammatory phase of disease seems to pre-date bone remodelling, and joint
13 tenderness often seems to improve in individuals over time (T.V.; unpublished data).

14

15 [H2] Genetics of hand OA

16 Genetic studies can provide powerful insights into pathogenesis. Hand OA has the highest estimated
17 heritability of all types of OA (approximately 60%)¹²¹. A comprehensive review published in 2008
18 summarised all genetic studies in hand, hip, knee and spine OA, drawing from literature published up until
19 2006¹²². This study revealed just two candidate gene associations that had been replicated for hand OA:
20 genetic variants in *ACAN* (encoding aggrecan, an integral component of the extracellular matrix in
21 cartilagenous tissue) and *HFE* (encoding homeostatic iron regulator, a protein associated with
22 hemochromatosis)¹²². Since this study, five genome wide association studies (GWAS)^{123,124,125,126,127} and
23 numerous candidate gene studies have been published. For convenience gene candidates can be grouped
24 into three areas according to their putative role in disease (Figure 2); those that are associated with growth
25 factor signalling^{124,125,128,129,130,131}, those that contribute to the integrity and calcification of the extracellular
26 matrix of cartilage^{123,126,132,133,134,135,136}, and those that relate to inflammatory pathways^{127,137,138,139,140,141}.
27 Two GWAS in hand OA deserve further attention. The first was a study in Iceland in which two loci were

1 identified: one on chromosome 1, a rare variant associated with severe hand OA (no further allelic
2 characterisation was given), and a second common set of variants on chromosome 15, all in *ALDH1A2*¹²⁷.
3 *ALDH1A2* encodes the enzyme retinal dehydrogenase 2 (ALDH1A2) that catalyses the synthesis of cellular
4 retinoic acid. The polymorphic variants in *ALDH1A2* are hypomorphic (that is, associated with lower levels
5 of ALDH1A2 in hand OA cartilage¹⁴². Retinoic acid is essential for forelimb development in the embryo and
6 is a potentially interesting target as this metabolite has anti-inflammatory effects on many different cell
7 types including chondrocytes¹⁴³. Paradoxically, chondrocyte biologists use retinoic acid to stimulate
8 cartilage catabolism (albeit at supra-physiological levels¹⁴⁴.

9
10 The second study, a 2017 GWAS from the Netherlands, identified a locus on chromosome 12, close to *MGP*
11¹²⁶. This gene, also identified in a previous candidate gene study¹³⁴, encodes matrix Gla protein (MGP),
12 which is responsible for preventing calcification of cartilage; the hypomorphic function associated with the
13 risk variant might predispose individuals to abnormal chondrocalcinosis and altered biomechanical
14 properties of the cartilage. MGP is known to be regulated by transforming growth factor beta (TGF β), so it
15 is of interest that candidate gene studies from the past few years have added further support for the
16 association of hand OA with polymorphic variants in genes encoding TGF β family members^{137,133,132}. These
17 associations are consistent with the purported chondroprotective role of TGF β in the joint.

19 [H2] Sex hormones and hand OA

20 All types of OA have a higher prevalence in post-menopausal women than in pre-menopausal women, but
21 the relationship that hand OA has with the typical time of the menopause onset seems to be unique and
22 robust^{26,145}. For instance, perimenopausal symptoms (such as hot flashes, irregular menstrual cycles)
23 commonly occur at the time of presentation with hand OA¹⁴⁵. Whether this relationship is due to the loss
24 of the established anti-inflammatory and pro-reparative effects of oestrogen or related to fluctuations in
25 other sex hormones is currently unclear. Both oestrogen and testosterone regulate ALDH1A expression¹⁴⁶,
26 and it is tempting to speculate that there might be important cross talk between retinoic acid and
27 oestrogen signalling in the perimenopausal period.

1

2 [H2] Inflammation and hand OA

3 The role of inflammation in hand OA remains particularly contentious. Although it is widely accepted that
4 inflammatory changes (including clinical and imaging-based synovitis) occur in disease, these changes are
5 typically relatively modest in hand OA compared with inflammatory arthritides such as RA¹⁴⁷, and the
6 pathogenic role of inflammation is far from certain. Data from prospective imaging studies show that
7 baseline synovitis on MRI or ultrasonography predicts radiographic progression and central erosion,
8 respectively^{99, 148, 116, 115}. However, it is worth bearing in mind that the presence of bone marrow lesions and
9 joint space narrowing also predict progressive disease⁹⁹, so it is possible that inflammation is a
10 consequence rather than cause of progressive disease.

11

12 A wide range of OA serum or plasma biomarkers have been investigated in hand OA, which can provide
13 insight into disease development. These biomarkers include various inflammatory markers, such as C-
14 reactive protein and adipokines, and markers of cartilage or bone homeostasis, such as type II collagen
15^{149, 150}. In one small sub-study of 18 patients from a 2016 hand OA clinical trial, serum IL-1 levels were
16 associated with loss of hand function and radiological erosions¹⁵¹. Although erosive and non-erosive hand
17 OA seem to have different biomarker profiles, to date biomarker characterization remains less developed
18 for hand OA than it is for OA at other sites such as the knee. Currently there are no validated serum or
19 plasma biomarkers for diagnosing hand OA, stratifying its severity, predicting its progression or response to
20 treatment.

21

22 Results from clinical trials can also aid in the understanding of disease pathogenesis. Intra-articular steroid
23 therapy is routinely used in many cases to treat symptomatic hand OA. A 2015 randomised controlled study
24 of 60 patients with symptomatic hand OA showed that steroid (triamcinolone) injection in combination
25 with lidocaine (a local anaesthetic) resulted in a statistically significant improvement in the patients hands,
26 in terms of pain on movement and physician's assessment of swelling, compared with treatment with
27 lidocaine alone¹⁵². Interestingly, lidocaine injection alone resulted in a striking response in the patients in

1 this study and five secondary disease activity measures did not differ between the two groups. The
2 emphasis on targeting inflammation in hand OA has been further unsettled by the negative results of
3 several randomised controlled studies in hand OA using traditional anti-inflammatory or ‘anti-synovial’
4 agents. These findings include a failure to demonstrate a difference between placebo treatment and
5 treatment with hydroxychloroquine^{153,154}, anti-TNF agents^{155,156} or IL-1 targeting strategies¹⁵⁷.

6

7 **[H1] Advances in therapy**

8 The management of hand OA combines both non-pharmacological and pharmacological approaches.
9 Surgical treatments are offered to those with severe symptoms and for whom conservative approaches
10 have failed²⁹. In this section we describe findings from original studies produced within the past five years
11 for core recommendations (a range of self-management support), first line analgesia and novel
12 pharmacological targets.

13

14 [H2] Non-pharmacological therapies

15 In a 2017 systemic review, Lue and colleagues¹⁵⁸ provided an update on an earlier review of non-surgical
16 therapies for hand OA^{Mahendira 2009} and the reader is directed to this manuscript for an appraisal of the
17 quality of some of the studies discussed below. In this section, a summary of the core and adjunctive
18 treatments and surgery are briefly provided.

19

20 *[H3] Core Interventions: self-management support*

21 Self-management programmes for hand OA can include a range of approaches such as providing the
22 patient with written information on hand OA and self-management approaches, giving advice on hand
23 exercises and joint education (such as joint protection strategies and pacing of activities), weight
24 management strategies, and using new models of care^{159,160}. For example, Moe *et al.*¹⁶⁰ concluded that the
25 use of an integrated, multidisciplinary care model, although not superior in clinical outcomes, resulted in
26 greater patient-reported satisfaction compared with usual care.

27

1 Written information on the underlying disease and self-management approaches, such as the OA
2 guidebook¹⁶¹, are an essential component of the core management of hand OA, although limited evidence
3 is available for the effectiveness of hand OA education alone. In the trial that tested a OA consultation
4 model (which consisted of an OA guidebook, an OA consultation with a GP, and a subsequent follow up
5 with a practice nurse in a dedicated OA clinic), the supply of written information by general practitioners
6 and practice nurses to patients increased from 4% to 28% in the model OA consultation arm, whereas no
7 changes from baseline were observed in the control arm (which consisted of usual care alongside a
8 resource pack of written advice for patients)¹⁶². Although implementation of this model did not improve
9 the health status of patients, it did improve the implementation of clinical guidelines (the NICE OA
10 recommendations) by clinicians and allied health professionals, along with the use of self-management
11 approaches¹⁵⁹.

12

13 Education on maintaining joint health is often described as 'joint protection education' or 'joint education'.
14 In the SMOoTH (Self-management of Osteoarthritis of the Hand) study, which included community dwelling
15 adults (aged 50 years and over) with ACR-defined hand OA, the individuals who attended occupational
16 therapy classes for joint protection education (using written patient information from a Arthritis Research
17 UK booklet¹⁶³) were twice as likely to respond to treatment than those did not attend the classes¹⁶⁴.

18

19 Several trials of hand exercise for hand OA^{165,166,167} have been published in the past few years, along with a
20 Cochrane systematic review¹⁶⁸. Exercise is recognised as an effective analgesic therapy for those with OA at
21 any site¹⁶⁹. However, despite continued efforts to identify the specific benefits of exercises for hand OA,
22 the Cochrane review¹⁶⁸ found that the magnitude of the benefit of exercise and which exercises should be
23 prescribed are still uncertain. For complex interventions, blinding the therapist or patient to the
24 intervention is difficult, and in large studies, self-report questionnaires are often used, which contribute to
25 a low quality rating of the study when assessed in systematic reviews. The findings suggest that
26 recommending one approach to exercise over another is not possible at present for hand OA. Few studies
27 have investigated the cost effectiveness of exercise in the management of hand OA but findings from the

1 SMOotH study show that hand exercises, delivered in classes by occupational therapists, could be a cost
2 effective approach over 12 months⁶⁶.

3

4 The association of obesity and hand OA is continually debated^{170,171}. Weight management forms part of an
5 holistic approach to managing OA in general and as hand OA often co-exists with OA in other sites,
6 consultations for hand OA provide an opportunity to offer weight management advice and referral to
7 services if a patient is overweight, as recommended by NICE quality standards^{8,9}.

8

9 *[H3] Adjunctive conservative therapies*

10 Several systematic reviews have been published in the past few years on the use of non-surgical treatments
11 for first CMJ OA^{172,173}. Local treatments such as splints (pre-fabricated or custom orthotics worn on the
12 affected joint) might offer warmth, support and stabilisation of joints that are normally painful on
13 movement. However, there continues to be uncertainty about the exact mechanism of action of splints,
14 and their optimal design and instructions for use to maximise adherence and safety. Soft splints, off the
15 shelf splints and splints worn at night time might be more acceptable to patients than hard splints, custom
16 made splints, or splints to be worn during the day^{174,175,176}.

17

18 Researchers have investigated splints or orthoses for first CMJ OA^{177,178,179,180,181} or IPJ OA^{182,173,172,158} as
19 well as pressure gloves for hand arthritis¹⁸³. However, currently, what type of splint is best is unclear and
20 data are inconsistent as to whether splints provide symptom relief in the hand¹⁵⁸. The use of splints does
21 improve function and pinch strength in patients with first CMJ OA^{172,173}. Most studies of splinting have a
22 high risk of bias because of difficulties in establishing or maintaining participant blinding or including true
23 sham devices, but the inclusion of a placebo splint in new upcoming studies such as the OA of the thumb
24 therapy (OTTER) trial gives an opportunity to address some of the key limitations of previous trials of
25 splinting^{174,175,176}.

26

27 *[H3] Other non-pharmacological therapies*

1 Several other therapies that have been tested for the treatment of hand OA include Spa therapy¹⁸⁴, joint
2 mobilisation¹⁸⁵, taping^{Wade 2018}, and ultrasound therapy¹⁸⁶. Although evidence is limited for the efficacy of
3 such treatments, these approaches have been recommended in various clinical guidelines for the
4 management of hand OA such as the EULAR Hand OA recommendations^{29,187, 188}.

6 [H2] Pharmacological therapies

7 *[H3] First line analgesia: topical treatments*

8 Topical NSAIDs are recommended in international and national guidelines as a first line pharmacological
9 treatment option for symptomatic hand OA (owing to the superior safety profile to oral analgesics^{8, 187} and
10 improved efficacy compared with oral paracetamol¹⁸⁹ and placebo¹⁹⁰). Overall, topical NSAIDs are superior
11 to placebo for relieving pain and improving function in OA¹⁸⁹. Although salicylate gel is associated with
12 higher withdrawal rates owing to adverse events, the remaining topical NSAIDs are not associated with any
13 increased local or systemic adverse events¹⁹⁰. The benefits of topical NSAIDs have been summarised
14 elsewhere¹⁹¹ but there is still uncertainty over the relative efficacy of topical NSAIDs compared with the
15 efficacy of other topical treatments such as capsaicin.

16
17 Topical capsaicin, an extract of hot chilli pepper, is recommended for the treatment of OA pain⁸ but studies
18 of this treatment in hand OA are limited. In a 2014 systematic review¹⁹² of RCTs of topical capsaicin use
19 in OA, which included five double-blind RCTs and one case-crossover trial, only one study included patients
20 with hand OA. Capsaicin was reported to be safe and well-tolerated across all the included studies, with no
21 evidence of systemic toxicity; however, there was evidence that this treatment could exacerbate
22 inflammatory symptoms. Capsaicin might therefore be more suited to patients who lack inflammatory signs
23 and have persistent pain or neuropathic symptoms, which aligns with the use of capsaicin for neuropathic
24 pain associated with other conditions. This treatment is associated with mild burning at the application site,
25 which peaks after one week and declines over time¹⁹². Capsaicin treatment efficacy warrants further
26 investigation.

27

1 *[H3] Local analgesia*

2 Injecting drugs such as glucocorticoids directly into the joints provide local symptomatic relief and offers
3 another option in addition to core treatment. Interest in the use of intra-articular injection therapy in hand
4 OA continues ^{193,152,194,195,196,197}, as this approach is preferable to surgical approaches in elderly patients with
5 comorbidities ¹⁹⁷.

6
7 The benefits and harms of intra-articular therapies were assessed in a 2016 systematic literature review
8 and meta-analysis; this analysis included trials that investigated the efficacy or safety of any intra-articular
9 therapy in first CMJ and IPJ OA compared with placebo or other treatments for which pain was the main
10 outcome ¹⁹⁷. A total of 13 trials (including 864 patients with hand OA; 11 trials of patients with OA of the first CMJ
11 and 2 trials of patients with OA of the IPJs) were included. The results of a meta-analysis of two trials comparing intra-
12 articular corticosteroids and placebo treatment in patients with first CMJ OA indicated that intra-articular
13 corticosteroid resulted in no improvement in pain. Synthetic hyaluronan also seemed inefficacious compared with
14 placebo in patients with first CMJ OA. However, in one trial of patients with OA of the IPJ, the patients receiving
15 corticosteroids had considerable improvements in pain during movement compared with the patients receiving
16 placebo ¹⁵². The authors of the systematic review ¹⁹⁷ concluded that intra-articular injection of corticosteroids or
17 hyaluronan do not seem more effective than placebo in first CMJ OA. However, the placebo response can be large
18 and intra-articular use in combination with other modalities such as splinting might be a relevant option.

19

20 *[H3] Adjunctive analgesia*

21 Paracetamol is prescribed for hand OA if topical treatments are ineffective or not tolerated ⁸, although the
22 effect size of this therapy in the treatment of large joint OA might be smaller than previously thought ¹⁸⁹. If
23 ineffective, and following careful assessment of the risks and benefits to the individual, oral NSAIDs (such
24 as naproxen), cyclooxygenase (COX)-II inhibitors or opiates might be introduced. These drugs should
25 generally be used sparingly and only when required to limit the risk of toxicity. A proton pump inhibitor
26 should be prescribed along with NSAIDs to protect against NSAID-induced gastrointestinal adverse events
27 ¹⁹⁸. In a 2015 study of patients with first CMJ OA ¹⁹⁹, in the small number of participants included in the

1 final analysis (n=19), the patients receiving naproxen had a considerable reduction in brain activity in areas
2 commonly associated with pain perception compared with those patients receiving placebo.

3

4 The use of several novel agents have been investigated for the treatment of hand OA and typically involve
5 the re-purposing of disease modifying anti-rheumatic drugs or biologic therapies licensed for use in RA:
6 these therapies include adalimumab, a monoclonal antibody to TNF¹⁵⁵, hydroxychloroquine¹⁵⁴, doxycycline
7²⁰⁰ and GCSB-5, a herb extract²⁰¹. Evidence from these studies suggest that adalimumab and
8 hydroxychloroquine are not effective in treating hand OA pain^{155,154}. Further studies are much needed to
9 identify oral treatments that improve hand pain or modify the course of disease. A number of drug trials in
10 OA, including ongoing trials, might be relevant to hand OA and have been reviewed elsewhere²⁰². The
11 ongoing clinical trials include drugs that inhibit inflammatory mechanisms (such as GM-CSF²⁰³ and anti-IL-6
12²⁰⁴) but novel targets relevant to other OA mechanisms might be needed to move the field forward.

13

14 Nutraceuticals are not recommended by NICE for the management of OA, but researchers have
15 investigated their effects in hand OA. In a systematic review of oral chondroitin for OA, including hand OA,
16 chondroitin treatment (alone or in combination with glucosamine) was associated with a short-term
17 benefit in terms of pain relief compared with placebo (albeit most of the studies assessed were of low
18 quality)²⁰⁵. The low risks associated with chondroitin might account for its popularity as an over-the-
19 counter supplement in individuals with hand OA, but more evidence is needed to advocate the use of this
20 supplement in routine clinical practice.

21

22 [H3] Surgery

23 Surgery in hand OA is recommended for patients who are refractory to non-surgical management⁸. In a
24 survey of 163 patients with first CMCJ OA, the results confirmed that patients predominantly
25 visit hand surgeons seeking treatment to reduce pain, and that improvements in function and aesthetic
26 image are a lower priority for these patients²⁰⁶. The findings highlight the need to elicit patients'
27 expectations before treatment and to discuss potential treatment outcomes in order to achieve optimal

1 gain from surgery. Placebo-controlled RCTs for many surgical procedures carried out for the treatment of
2 hand OA are lacking.

3

4 **[H1] Guidelines and implementation**

5 Guidelines have previously been published that address the clinical management of hand OA ^{207,208,8,29},
6 including the newly released 2018 update from EULAR ²⁰⁹. However ensuring the uptake of guidelines in
7 clinical practice is challenging ^{159, 162}. Improvements are needed in ways of recording hand OA diagnosis in
8 primary care and evaluating the quality of hand OA care, including the implementation of guidelines.
9 Demonstrating an association between the implementation of clinical guidelines and improvements in the
10 health status and function of patients is difficult in real world settings ¹⁵⁹. This field of investigation is
11 growing; for example, ways in which to measure the quality of care that include valid quality indicators and
12 demonstrate the effects of implementation are now high on the research agenda.

13

14 Regarding research guidelines, a preliminary core set of outcomes has been developed by OMERACT using
15 Delphi exercises and systematic literature review ²¹⁰. In clinical trials of symptom modification, the
16 minimum outcomes should include assessments of pain, physical function, global patient assessment, joint
17 activity and hand strength. For clinical trials examining structure modification as well as observational
18 studies, structural damage should also be examined ²¹⁰. Finally, guidelines on imaging in hand OA clinical
19 trials are also available ⁷¹.

20

21 **[H1] Conclusion**

22 Hand OA is a common, disabling, heterogeneous condition. Studies in the past few years have provided
23 some advances in our understanding of the burden and underlying mechanisms of hand OA as well as in
24 hand OA therapy, but there is much still to understand. Localised therapies for hand OA such as hand
25 exercises and topical treatments offer small but clinically important amounts of symptomatic relief in hand
26 OA and should arguably be more widely used. Hydroxychloroquine, previously used anecdotally off-label to
27 treat severe forms of the disease, is now known to be an ineffective in the treatment of established

1 symptomatic radiographic hand OA and should not be used in such patients. The lack of efficacy of many
2 anti-rheumatic drugs in hand OA has catalysed a re-evaluation of potential disease targets. The
3 disappointing results from clinical trials reaffirm the need for a better understanding of basic underlying
4 disease mechanisms, and arguably a better method for identifying and stratifying patient with early disease
5 and/or who have at high risk of progression, at a time when diseases processes might be susceptible to
6 intervention.

7

8 In primary care management, the diagnosis of hand OA without the use of imaging is still recommended by
9 international guidelines⁸. A better approach for classifying and coding the disease is needed. Such an
10 approach is essential for improving the delivery of quality care for this common condition. Guidelines such
11 as the newly updated 2018 EULAR recommendations²⁰⁹ for the management of hand OA will continue to
12 improve the quality of care for patients with hand OA, provided that steps are taken to accelerate the
13 implementation of such guidance into every day practice.

14

15

References

1. Global Burden of Disease Study 2013 Collaborators. Global, regional, and national incidence, prevalence, and years lived with disability for 301 acute and chronic diseases and injuries in 188 countries, 1990–2013: a systematic analysis for the Global Burden of Disease Study 2013. *Lancet*. **386**, 743-800 (2015).
2. Cross, M. *et al.* The global burden of hip and knee osteoarthritis: estimates from the global burden of disease 2010 study. *Ann. Rheum. Dis.* **73**, 1323-1330 (2015).
3. Dziedzic, K. *et al.* The impact of musculoskeletal hand problems in older adults: findings from the North Staffordshire Osteoarthritis Project (NorStOP). *Rheumatology (Oxford)*. **46**, 963-967 (2007).
4. Kloppenburg, M, & Kwok, W. Y. Hand osteoarthritis - a heterogeneous disorder. *Nat. Rev. Rheumatol.* **8**, 22-31 (2011).
5. Marshall, M. *et al.* Subsets of symptomatic hand osteoarthritis in community-dwelling older adults in the United Kingdom: prevalence, inter-relationships, risk factor profiles and clinical characteristics at baseline and 3-years. *Osteoarthritis Cartilage*. **21**, 1674-1684 (2013).
6. Kloppenburg, M. Hand osteoarthritis-nonpharmacological and pharmacological treatments. *Nat. Rev. Rheumatol.* **10**, 242-251 (2014).
7. EIT Health. Joint Implementation of Guidelines for oSteoArthritis in Western Europe (JIGSAW-E). *EIT Health*. <https://www.eithealth.eu/jigsaw-e> (2017).
8. National Institute for Health & Care Excellence. *NICE Clinical Guideline [CG177] Osteoarthritis: Care and Management in Adults*. (National Institute for Health & Care Excellence, London, 2014).
9. National Institute for Health & Care Excellence. National Institute for Health & Care Excellence Quality Standard for Osteoarthritis (NICE Quality Standard 87). (National Institute for Health & Care Excellence, Manchester, 2015).
10. Dziedzic, K. S. *et al.* Self management, joint protection and exercises in hand osteoarthritis: a randomised controlled trial with cost effectiveness analyses. *BMC Musculoskelet. Disord.* **12**, 156 (2011).
11. Marshall, M. *et al.* Radiographic hand osteoarthritis: patterns and associations with hand pain and function in a community-dwelling sample. *Osteoarthritis Cartilage*. **17**, 1440-1447 (2009).

12. Hammer, H. B. *et al.* Global ultrasound assessment of structural lesions in osteoarthritis: a reliability study by the OMERACT ultrasonography group on scoring cartilage and osteophytes in finger joints. *Ann. Rheum. Dis.* **75**, 402-407 (2016).
13. Srikanth, V. K. *et al.* A meta-analysis of sex differences prevalence, incidence and severity of osteoarthritis. *Osteoarthritis Cartilage.* **13**, 769-781 (2005).
14. Punzi L., Ramonda, R. & Sfriso, P. Erosive osteoarthritis. *Best. Pract. Res. Clin. Rheumatol.* **18**, 739-758 (2004).
15. Pereira, D. *et al.* The effect of osteoarthritis definition on prevalence and incidence estimates: a systematic review. *Osteoarthritis Cartilage.* **19**, 1270-1285 (2011).
16. Sowers, M., Lachance, L., Hochberg, M. & Jamadar, D. Radiographically defined osteoarthritis of the hand and knee in young and middle-aged African American and Caucasian women. *Osteoarthritis Cartilage.* **8**, 69-77 (2000).
17. Kodama, R. *et al.* Prevalence of hand osteoarthritis and its relationship to hand pain and grip strength in Japan: The third survey of the ROAD study. *Mod. Rheumatol.* **26**, 767-773 (2016).
18. Davatchi, F. *et al.* Epidemiology of rheumatic diseases in Iran from analysis of four COPCORD studies. *Int. J. Rheum. Dis.* **19**, 1056-1062 (2016).
19. Zhang, Y. *et al.* Lower prevalence of hand osteoarthritis among Chinese subjects in Beijing compared with white subjects in the United States: the Beijing Osteoarthritis Study. *Arthritis Rheum.* **48**, 1034-1040 (2003).
20. Haugen, I. K. *et al.* Prevalence, incidence and progression of hand osteoarthritis in the general population: the Framingham Osteoarthritis Study. *Ann. Rheum. Dis.* **70**, 1581-1586 (2011).
21. Tomi, A-L. *et al.* Increased prevalence and severity of radiographic hand osteoarthritis in patients with HIV-1 infection associated with metabolic syndrome: data from the cross-sectional METAFIB-OA study. **75**, 2101-2107 (2016)
22. Qin, J. *et al.* Lifetime Risk of Symptomatic Hand Osteoarthritis: The Johnston County Osteoarthritis Project. *Arthritis Rheumatol.* **69**, 1204-1212 (2017).

23. Kallman, D. A., Wigley, F. M., Scott, W. W. Jr., Hochberg, M. C. & Tobin, J. D. The longitudinal course of hand osteoarthritis in a male population. *Arthritis Rheum.* **33**, 1323-1332 (1990).
24. Haugen, I. K., Magnusson, K., Turkiewicz, A. & Englund, M. The Prevalence, Incidence, and Progression of Hand Osteoarthritis in Relation to Body Mass Index, Smoking, and Alcohol Consumption. *J. Rheumatol.* **44**, 1402-1409 (2017).
25. Oliveria, S. A., Felson, D. T., Reed, J. I., Cirillo, P. A. & Walker, A. M. Incidence of symptomatic hand, hip, and knee osteoarthritis among patients in a health maintenance organization. *Arthritis Rheum.* **38**, 1134-1141 (1995).
26. Prieto-Alhambra, D. *et al.* Incidence and risk factors for clinically diagnosed knee, hip and hand osteoarthritis: influences of age, gender and osteoarthritis affecting other joints. *Ann. Rheum. Dis.* **73**, 1659-1664 (2014).
27. Botha-Scheepers, S.A. *et al.* Influence of familial factors on radiologic disease progression over two years in siblings with osteoarthritis at multiple sites: a prospective longitudinal cohort study. *Arthritis Rheum.* **57**, 626-632 (2007).
28. Haugen, I. K., Slatkowsky-Christensen, B., Faraj, K., van der Heijde, D. & Kvien, T. K. The comparison of magnetic resonance imaging and radiographs to assess structural progression over 5 years in hand osteoarthritis. *Rheumatology (Oxford)*. **56**, 371-377 (2017). Zhang, W. *et al.* EULAR evidence based recommendations for the management of hand osteoarthritis: report of a Task Force of the EULAR Standing Committee for International Clinical Studies Including Therapeutics (ESCISIT). *Ann. Rheum. Dis.* **66**, 377-388 (2007).
29. Tan, A. L. *et al.* High-resolution magnetic resonance imaging for the assessment of hand osteoarthritis. *Arthritis Rheum.* **52**, 2355-2365 (2005).
30. Villafañe, J. H. & Valdes, K. Combined thumb abduction and index finger extension strength: a comparison of older adults with and without thumb carpometacarpal osteoarthritis. *J. Manipulative. Physiol. Ther.* **36**, 238-244 (2013).

31. Cantero-Téllez, R., Martín-Valero, R. & Cuesta-Vargas, A. Effect of muscle strength and pain on hand function in patients with trapeziometacarpal osteoarthritis. A cross-sectional study. *Reumatol Clin.* **11**, 340-344 (2015).
32. McQuillan, T. J., Kenney, D., Crisco, J. J., Weiss, A. P. & Ladd, A. L. Weaker Functional Pinch Strength Is Associated With Early Thumb Carpometacarpal Osteoarthritis. *Clin. Orthop. Relat. Res.* **474**, 557-561 (2016).
33. Coughlan, M. J. *et al.* Reduction in Cylindrical Grasp Strength Is Associated With Early Thumb Carpometacarpal Osteoarthritis. *Clin. Orthop. Relat. Res.* **475**, 522-528 (2017).
34. Mobargha, N., Ludwig, C., Ladd, A. L. & Hagert, E. Ultrastructure and innervation of thumb carpometacarpal ligaments in surgical patients with osteoarthritis. *Clin. Orthop. Relat. Res.* **472**, 1146-1154 (2014).
35. Mallinson, P. I., Tun, J. K., Farnell, R. D., Campbell, D. A. & Robinson, P. Osteoarthritis of the thumb carpometacarpal joint: correlation of ultrasound appearances to disability and treatment response. *Clin. Radiol.* **68**, 461-465 (2013).
36. Dumont, C *et al.* Osteoarthritis of the carpometacarpal joint of the thumb: a new MR imaging technique for the standardized detection of relevant ligamentous lesions. *Skeletal Radiol.* **43**, 1411-1420 (2014).
37. Merritt, M. M., Roddey, T. S., Costello, C. & Olson, S. Diagnostic value of clinical grind test for carpometacarpal osteoarthritis of the thumb. *J. Hand Ther.* **23**, 261-267, (2010).
38. Choa, R. M., Parviz, N. & Giele, H. P. A prospective case-control study to compare the sensitivity and specificity of the grind and traction-shift (subluxation-relocation) clinical tests in osteoarthritis of the thumb carpometacarpal joint. *J. Hand Surg. Eur.* **39**, 282-285 (2014).
39. Rees, F. *et al.* Distribution of finger nodes and their association with underlying radiographic features of osteoarthritis. *Arthritis Care. Res. (Hoboken).* **64**, 533-538 (2012).
40. Thaper, A., Zhang, W., Wright, G. & Doherty, M. Relationship between Heberden's nodes and underlying radiographic changes of osteoarthritis. *Ann. Rheum. Dis.* **64**, 1214-1216 (2005).

41. Vlychou, M., Koutroumpas, A., Alexiou, I., Fezoulidis, I. & Sakkas, L. I. High-resolution ultrasonography and 3.0 T magnetic resonance imaging in erosive and nodal hand osteoarthritis: high frequency of erosions in nodal osteoarthritis. *Clin. Rheumatol.* **32**, 755-762 (2013).
42. Hodkinson, B., Maheu, E., Michon, M., Carrat, F. & Berenbaum, F. Assessment and determinants of aesthetic discomfort in hand osteoarthritis. *Ann. Rheum. Dis.* **71**, 45-49 (2012).
43. Altman, R. D. & Gold, G. E. Atlas of individual radiographic features in osteoarthritis, revised. *Osteoarthritis Cartilage.* **15**, A1-A56 (2007).
44. Verbruggen, G. & Veys, E. M. Numerical scoring systems for the anatomic evolution of osteoarthritis of the finger joints. *Arthritis Rheum.* **39**, 308-320 (1996).
45. Marshall, M. *et al.* Erosive osteoarthritis: a more severe form of radiographic hand osteoarthritis rather than a distinct entity? *Ann. Rheum. Dis.* **74**, 136-141 (2015).
46. Addimanda, O. *et al.* Clinical and radiographic distribution of structural damage in erosive and nonerosive hand osteoarthritis. *Arthritis Care. Res. (Hoboken).* **64**, 1046-1053 (2012).
47. Kwok, W. Y. *et al.* The prevalence of erosive osteoarthritis in carpometacarpal joints and its clinical burden in symptomatic community-dwelling adults. *Osteoarthritis Cartilage.* **22**, 756-763 (2014).
48. Kwok, W. Y. *et al.* Comparison of clinical burden between patients with erosive hand osteoarthritis and inflammatory arthritis in symptomatic community-dwelling adults: the Keele clinical assessment studies. *Rheumatology (Oxford).* **52**, 2260-2267 (2013).
49. Wittoek, R., Cruyssen, B. V., Verbruggen, G. Predictors of functional impairment and pain in erosive osteoarthritis of the interphalangeal joints: comparison with controlled inflammatory arthritis. *Arthritis Rheum.* **64**, 1430-1436 (2012). Kortekaas, M. C., Kwok, W. Y., Reijniere, M., Huizinga, T. W. & Kloppenburg, M. In erosive hand osteoarthritis more inflammatory signs on ultrasound are found than in the rest of hand osteoarthritis. *Ann. Rheum. Dis.* **72**, 930-934 (2013).
50. Haugen, I. K. *et al.* Synovitis and radiographic progression in non-erosive and erosive hand osteoarthritis: is erosive hand osteoarthritis a separate inflammatory phenotype? *Osteoarthritis Cartilage.* **24**, 647-654 (2016).

51. Bukhave, E. B. & Huniche, L. Activity problems in everyday life--patients' perspectives of hand osteoarthritis: "try imagining what it would be like having no hands". *Disabil. Rehabil.* **36**, 1636-1643 (2014).
52. Bukhave, E. B., la Cour, K. & Huniche, L. The meaning of activity and participation in everyday life when living with hand osteoarthritis. *Scand. J. Occup. Ther.* **21**, 24-30 (2014).
53. van Schoor, N. M. *et al.* Impact of clinical osteoarthritis of the hip, knee and hand on self-rated health in six European countries: the European Project on OsteoArthritis. *Qual. Life. Res.* **25**, 1423-1432 (2016).
54. Hall, A.J. *et al.* Association between osteoarthritis and cardiovascular disease: Systematic review and meta-analysis. **23**, 938-946 (2016).
55. Koutroumpas, A. *et al.* Erosive Hand Osteoarthritis is Associated with Subclinical Atherosclerosis and Endothelial Dysfunction. **9**, 217-223 (2013)
56. Jonsson, H. *et al.* Hand osteoarthritis in older women is associated with carotid and coronary atherosclerosis: the AGES Reykjavik study **68**, 1696-1700 (2009).
57. Courties, A. *et al.* Coronary heart disease is associated with a worse clinical outcome of hand osteoarthritis: a cross-sectional and longitudinal study. **3**, e000344 (2017).
58. Haugen, I.K. *et al.* Hand osteoarthritis in relation to mortality and incidence of cardiovascular disease: data from the Framingham Heart Study. *ARD* **74**, 74-81 (2015). Kluzek, S. *et al.* Painful knee but not hand osteoarthritis is an independent predictor of mortality over 23 years follow-up of a population-based cohort of middle-aged women. *Ann. Rheum. Dis.* **75**, 1749-1756 (2016).
59. Liu, R. *et al.* Mortality in osteoarthritis patients. *Scand. J. Rheumatol.* **44**, 70-73 (2015).
60. Neuprez, A. *et al.* Aesthetic discomfort in hand osteoarthritis: results from the Liège Hand Osteoarthritis Cohort (LIHOC). *Arthritis Res. Ther.* **17**, 346 (2015).
61. Liu, R., Damman, W., Kaptein, A. A., Rosendaal, F.R. & Kloppenburg, M. Coping styles and disability in patients with hand osteoarthritis. *Rheumatology (Oxford)*. **55**, 411-418 (2016).
62. Gilpin, H. R., Moseley, G. L., Stanton, T. R. & Newport, R. Evidence for distorted mental representation of the hand in osteoarthritis. *Rheumatology (Oxford)*. **54**, 678-682 (2015).

63. Oppong, R. *et al.* Joint protection and hand exercises for hand osteoarthritis: an economic evaluation comparing methods for the analysis of factorial trials. *Rheumatology (Oxford)*. **54**, 876-883 (2015).
64. Becker, S. J. *et al.* Medical services and associated costs vary widely among surgeons treating patients with hand osteoarthritis. *Clin. Orthop. Relat. Res.* **473**, 1111-1117 (2015).
65. Marks, M. *et al.* Healthcare costs and loss of productivity in patients with trapeziometacarpal osteoarthritis. *J. Hand. Surg. Eur.* **40**, 927-934 (2015).
66. Wolf JM, Atroshi I, Zhou C, Karlsson J. & Englund M. Sick Leave After Surgery for Thumb Carpometacarpal Osteoarthritis: A Population-Based Study. *J. Hand Surg. Am.* (2018). [Epub ahead of print doi: 10.1016/j.jhsa.2017.11.019].
67. Kloppenburg, M. *et al.* OARSI Clinical Trials Recommendations: Design and conduct of clinical trials for hand osteoarthritis. *Osteoarthritis Cartilage*. **23**, 772-786 (2015).
68. Hunter DJ, *et al.* OARSI Clinical Trials Recommendations: Hand imaging in clinical trials in osteoarthritis. *Osteoarthritis Cartilage*. **23**, 732-746 (2015).
69. Sakellariou, G. *et al.* EULAR recommendations for the use of imaging in the clinical management of peripheral joint osteoarthritis. *Ann. Rheum. Dis.* **76**, 1484-1494 (2017).
70. Matsos, M. *et al.* Ultrasound of the hands and feet for rheumatological disorders: influence on clinical diagnostic confidence and patient management. *Skeletal Radiol.* **38**, 1049-1054 (2009).
71. Maheu, E. *et al.* Reproducibility and sensitivity to change of four scoring methods for the radiological assessment of osteoarthritis of the hand. *Ann. Rheum. Dis.* **66**, 464-469 (2007).
72. Bijsterbosch, J. *et al.* Reliability, sensitivity to change and feasibility of three radiographic scoring methods for hand osteoarthritis. *Ann. Rheum. Dis.* **70**, 1465-1467 (2011). Keen, H.I. *et al.* Can ultrasonography improve on radiographic assessment in osteoarthritis of the hands? A comparison between radiographic and ultrasonographic detected pathology. *Ann. Rheum. Dis.* **67**, 1116-1120 (2008).
73. Abraham, A. M., Pearce, M. S., Mann, K. D., Francis, R. M. & Birrell, F. Population prevalence of ultrasound features of osteoarthritis in the hand, knee and hip at age 63 years: the Newcastle thousand families birth cohort. *BMC Musculoskelet. Disord.* **15**, 162 (2014).

74. Usón, J. *et al.* Symptomatic and asymptomatic interphalangeal osteoarthritis: An ultrasonographic study. *Reumatol Clin.* **10**, 278-282 (2014).
75. Mathiessen, A. *et al.* Ultrasonographic assessment of osteophytes in 127 patients with hand osteoarthritis: exploring reliability and associations with MRI, radiographs and clinical joint findings. *Ann. Rheum. Dis.* **72**, 51-56 (2013).
76. Haugen, I. K. *et al.* Comparison of features by MRI and radiographs of the interphalangeal finger joints in patients with hand osteoarthritis. *Ann. Rheum. Dis.* **71**, 345-350 (2012).
77. Keen, H. I. *et al.* An ultrasonographic study of osteoarthritis of the hand: synovitis and its relationship to structural pathology and symptoms. *Arthritis Rheum.* **59**, 1756-1763 (2008).
78. Kortekaas, M. C. *et al.* Pain in hand osteoarthritis is associated with inflammation: the value of ultrasound. *Ann. Rheum. Dis.* **69**, 1367-1369 (2010).
79. Tan, A. L. *et al.* High-resolution magnetic resonance imaging for the assessment of hand osteoarthritis. *Arthritis Rheum.* **52**, 2355-2365 (2005).
80. Liu R, *et al.* Bone marrow lesions on magnetic resonance imaging in hand osteoarthritis are associated with pain and interact with synovitis. *Osteoarthritis Cartilage.* **25**, 1093-1099 (2017). Keen, H. I. *et al.* The development of a preliminary ultrasonographic scoring system for features of hand osteoarthritis. *Ann. Rheum. Dis.* **67**, 651-655 (2008).
81. Iagnocco, A. *et al.* The reliability of musculoskeletal ultrasound in the detection of cartilage abnormalities at the metacarpo-phalangeal joints. *Osteoarthritis Cartilage.* **20**, 1142-1146 (2012).
82. Wittoek, R. *et al.* Reliability and construct validity of ultrasonography of soft tissue and destructive changes in erosive osteoarthritis of the interphalangeal finger joints: a comparison with MRI. *Ann. Rheum. Dis.* **70**, 278-283 (2011).
83. Kortekaas, M. C., Kwok, W. Y., Reijniere, M., Huizinga, T.W. & Kloppenburg, M. Osteophytes and joint space narrowing are independently associated with pain in finger joints in hand osteoarthritis. *Ann. Rheum. Dis.* **70**, 1835-1837 (2011).
84. Spolidoro Paschoal, N. O. *et al.* Interphalangeal Joint Sonography of Symptomatic Hand Osteoarthritis: Clinical and Functional Correlation. *J. Ultrasound Med.* **36**, 311-319 (2017). Guermazi, A., Roemer, F. W.

- & Hayashi, D. Imaging of osteoarthritis: update from a radiological perspective. *Curr. Opin. Rheumatol.* **23**, 484-491 (2011).
- 85.Haugen, I. K. *et al.* Hand osteoarthritis and MRI: development and first validation step of the proposed Oslo Hand Osteoarthritis MRI score. *Ann. Rheum. Dis.* **70**, 1033-1038 (2011).
- 86.Haugen, I. K. *et al.* Associations between MRI-defined synovitis, bone marrow lesions and structural features and measures of pain and physical function in hand osteoarthritis. *Ann. Rheum. Dis.* **71**, 899-904 (2012).
- 87.Kortekaas, M. C. *et al.* Magnetic Resonance Imaging in Hand Osteoarthritis: Intraobserver Reliability and Criterion Validity for Clinical and Structural Characteristics. *J. Rheumatol.* **42**, 1224-1230 (2015). Ramonda, R. *et al.* A recently developed MRI scoring system for hand osteoarthritis: its application in a clinical setting. *Clin. Rheumatol.* **35**, 2079-2086 (2016).
- 88.Haugen, I. K. *et al.* Iterative development and reliability of the OMERACT hand osteoarthritis MRI scoring system. *J. Rheumatol.* **41**, 386-391 (2014).
- 89.Haugen, I. K. *et al.* The Longitudinal Reliability and Responsiveness of the OMERACT Hand Osteoarthritis Magnetic Resonance Imaging Scoring System (HOAMRIS). *J. Rheumatol.* **42**, 2486-2491 (2015).
- 90.Haugen, I. K. *et al.* Increasing synovitis and bone marrow lesions are associated with incident joint tenderness in hand osteoarthritis. *Ann. Rheum. Dis.* **75**, 702-708 (2016).
- 91.Damman, W. *et al.* Bone marrow lesions and synovitis on MRI associate with radiographic progression after 2 years in hand osteoarthritis. *Ann. Rheum. Dis.* **76**, 214-217 (2017).
- 92.Haugen, I. K. *et al.* MRI findings predict radiographic progression and development of erosions in hand osteoarthritis. *Ann. Rheum. Dis.* **75**, 117-123 (2016).
- 93.Kortekaas, M. C., Kwok, W. Y., Reijniere, M. & Kloppenburg, M. Inflammatory ultrasound features show independent associations with progression of structural damage after over 2 years of follow-up in patients with hand osteoarthritis. *Ann. Rheum. Dis.* **74**, 1720-1724 (2015).

94. Mathiessen, A., Slatkowsky-Christensen, B., Kvien, T. K., Hammer, H. B. & Haugen, I. K. Ultrasound-detected inflammation predicts radiographic progression in hand osteoarthritis after 5 years. *Ann. Rheum. Dis.* **75**, 825-830 (2016).
95. Keen, H. I., Wakefield, R. J., Hensor, E. M., Emery, P. & Conaghan, P. G. Response of symptoms and synovitis to intra-muscular methylprednisolone in osteoarthritis of the hand: an ultrasonographic study. *Rheumatology (Oxford)*. **49**, 1093-1100 (2010).
96. Klauser, A. S. *et al.* Sonographic criteria for therapy follow-up in the course of ultrasound-guided intra-articular injections of hyaluronic acid in hand osteoarthritis. *Eur. J. Radiol.* **81**, 1607-1611 (2012)
97. Kortekaas, M. C. *et al.* Follow-up study of inflammatory ultrasound features in hand osteoarthritis over a period of 3 months: variable as well as constant. *Osteoarthritis Cartilage*. **22**, 40-43 (2014). Finzel, S. *et al.* Inflammatory bone spur formation in psoriatic arthritis is different from bone spur formation in hand osteoarthritis. *Arthritis Rheumatol.* **66**, 2968-2975 (2014).
98. Halilaj, E. *et al.* The morphology of the thumb carpometacarpal joint does not differ between men and women, but changes with aging and early osteoarthritis. *J. Biomech.* **47**, 2709-2714 (2014).
99. Lee, A.T. *et al.* Trapezium trabecular morphology in carpometacarpal arthritis. *J. Hand. Surg. Am.* **38**, 309-315 (2013).
100. Zhang, Y. Optical Imaging. *NIH Fact Sheet*.
<https://report.nih.gov/NIHfactsheets/ViewFactSheet.aspx?csid=105> (2013).
101. Gompels, L. L., Lim, N. H., Vincent, T. & Paleolog, E. M. In vivo optical imaging in arthritis--an enlightening future? *Rheumatology (Oxford)*. **49**, 1436-1446 (2010).
102. Haugen, I. K., Slatkowsky-Christensen, B., Bøyesen, P., van der Heijde, D. & Kvien, T. K. Cross-sectional and longitudinal associations between radiographic features and measures of pain and physical function in hand osteoarthritis. *Osteoarthritis Cartilage*. **21**, 1191-1198 (2013).
103. Barr, A. J. *et al.* A systematic review of the relationship between subchondral bone features, pain and structural pathology in peripheral joint osteoarthritis. *Arthritis Res. Ther.* **17**, 228 (2015).
104. Usón, J. Symptomatic and Asymptomatic Interphalangeal Osteoarthritis: An Ultrasonographic Study. *Reumatol. Clin.* **10**, 278-282 (2014).

105. Magnusson, K. *et al.* Diabetes is associated with increased hand pain in erosive hand osteoarthritis: data from a population-based study. *Arthritis Care Res. (Hoboken)*. **67**, 187-195 (2015).
106. Lee, H.J., Paik, N.J., Lim, J. Y., Kim, K.W. & Gong, H. S. The impact of digit-related radiographic osteoarthritis of the hand on grip-strength and upper extremity disability. *Clin. Orthop. Relat. Res.* **470**, 2202-2208 (2012).
107. Mancarella, L. *et al.* Ultrasound detected inflammation is associated with the development of new bone erosions in hand osteoarthritis: a longitudinal study over 3.9 years. *Osteoarthritis. Cartilage*. **23**, 1925-32 (2015).
108. Mancarella, L., Addimanda, O., Cavallari, C. & Meliconi, R. Synovial Inflammation Drives Structural Damage in Hand Osteoarthritis: a Narrative Literature Review. *Curr. Rheumatol. Rev.* **13**, 43-50 (2017).
109. Damman, W. *et al.* Do Comorbidities Play a Role in Hand Osteoarthritis Disease Burden? Data from the Hand Osteoarthritis in Secondary Care Cohort. *J. Rheumatol.* **44**, 1659-1666 (2017).
110. Brandt, K. D., Dieppe, P. & Radin, E. L. Commentary: Is It Useful to Subset 'Primary' Osteoarthritis? A Critique Based on Evidence Regarding the Etiopathogenesis of Osteoarthritis. *Semin. Arthritis Rheum.* **39**, 81–95 (2009).
111. Droz-Bartholet, F., Verhoeven, F., Prati, C. & Wendling, D. Prevention of Hand Osteoarthritis by Hemiparesis. *Arthritis Rheumatol.* **68**, 647 (2016).
112. Tan, A. L. *et al.* Combined high-resolution magnetic resonance imaging and histological examination to explore the role of ligaments and tendons in the phenotypic expression of early hand osteoarthritis. *Ann. Rheum. Dis.* **65**, 1267–1272 (2006).
113. Ishimori, M. L. *et al.* Heritability patterns in hand osteoarthritis: the role of osteophytes. *Arthritis Res. Ther.* **12**, R180 (2010).
114. Ryder, J. J. *et al.* Genetic associations in peripheral joint osteoarthritis and spinal degenerative disease: a systematic review. *Ann. Rheum. Dis.* **67**, 584–591 (2008).
115. Stefánsson, S. E. *et al.* Genomewide scan for hand osteoarthritis: a novel mutation in matrilin-3. *Am. J. Hum. Genet.* **72**, 1448–1459 (2003).

116. Zhai, G. *et al.* A genome-wide association study suggests that a locus within the ataxin 2 binding protein 1 gene is associated with hand osteoarthritis: the Treat-OA consortium. *J. Med. Genet.* **46**, 614–616 (2009).
117. Kerkhof, H. J. M. *et al.* A genome-wide association study identifies an osteoarthritis susceptibility locus on chromosome 7q22. *Arthritis Rheum.* **62**, 499–510 (2010).
118. Hollander, den, W. *et al.* Genome-wide association and functional studies identify a role for matrix Gla protein in osteoarthritis of the hand. *Ann. Rheum. Dis.* **76**, 2046–2053 (2017).
119. Styrkarsdottir, U. *et al.* Severe osteoarthritis of the hand associates with common variants within the ALDH1A2 gene and with rare variants at 1p31. *Nat. Genet.* **46**, 498–502 (2014).
120. Hämäläinen, S. *et al.* Genetic influences on hand osteoarthritis in Finnish women--a replication study of candidate genes. *PLoS ONE* **9**, e97417 (2014).
121. Zhang, R. *et al.* A comprehensive meta-analysis of association between genetic variants of GDF5 and osteoarthritis of the knee, hip and hand. *Inflamm. Res.* **64**, 405–414 (2015).
122. Zhang, F. *et al.* Association between KLOTHO gene and hand osteoarthritis in a female Caucasian population. *YJOCA* **15**, 624–629 (2007).
123. Meulenbelt, I. *et al.* A genetic association study of the IGF-1 gene and radiological osteoarthritis in a population-based cohort study (the Rotterdam Study). *Ann. Rheum. Dis.* **57**, 371–374 (1998).
124. Bijsterbosch, J. *et al.* Association study of candidate genes for the progression of hand osteoarthritis. *Osteoarthritis Cartilage* **21**, 565–569 (2013).
125. Taipale, M., Solovieva, S., Leino-Arjas, P. & Männikkö, M. Functional polymorphisms in asporin and CILP together with joint loading predispose to hand osteoarthritis. *BMC Genet.* **18**, 108 (2017).
126. Misra, D. *et al.* Matrix Gla protein polymorphism, but not concentrations, is associated with radiographic hand osteoarthritis. *J Rheumatol* **38**, 1960–1965 (2011).
127. Suk, E.-K. *et al.* Association of ENPP1 gene polymorphisms with hand osteoarthritis in a Chuvasha population. *Arthritis Res. Ther.* **7**, R1082–90 (2005).
128. Kämäräinen, O.-P. *et al.* Aggrecan core protein of a certain length is protective against hand osteoarthritis. *YJOCA* **14**, 1075–1080 (2006).

129. Hämäläinen, S., Solovieva, S., Vehmas, T., Leino-Arjas, P. & Hirvonen, A. Variations in the TNF α gene and their interactions with the IL4R and IL10 genes in relation to hand osteoarthritis. *BMC Musculoskeletal Disord* **15**, 311 (2014).
130. Vargiolu, M. *et al.* Interleukin-4/interleukin-4 receptor gene polymorphisms in hand osteoarthritis. *Osteoarthritis Cartilage* **18**, 810–816 (2010).
131. Blumenfeld, O. *et al.* Association of interleukin-6 gene polymorphisms with hand osteoarthritis and hand osteoporosis. *Cytokine* **69**, 94–101 (2014).
132. Näkki, A. *et al.* Allelic variants of IL1R1 gene associate with severe hand osteoarthritis. *BMC Med. Genet.* **11**, 50 (2010).
133. Moxley, G., Han, J., Stern, A. G. & Riley, B. P. Potential influence of IL1B haplotype and IL1A-IL1B-IL1RN extended haplotype on hand osteoarthritis risk. *YJOCA* **15**, 1106–1112 (2007).
134. Zhu, L. *et al.* Polymorphic variants in ALDH1A2 determine the expression level of ALDH1A2 and CYP19A1 in the cartilage of patients undergoing trapeziectomy for severe thumb osteoarthritis. *Osteoarthritis Cartilage*. 26, S157 (2018). [Abstract]
135. Ho, L.J. *et al.* Retinoic acid blocks pro-inflammatory cytokine-induced matrix metalloproteinase production by down-regulating JNK-AP-1 signaling in human chondrocytes. *Biochemical Pharmacology*. **70**, 200–208 (2005).
136. Stanton, H. *et al.* Investigating ADAMTS-mediated aggrecanolysis in mouse cartilage. *Nat Protoc.* **6**, 388–404 (2011). Watt, F. E. Hand osteoarthritis, menopause and menopausal hormone therapy. *Maturitas.* **83**, 13–18 (2016).
137. Petrosino, J. M., Disilvestro, D. & Ziouzenkova, O. Aldehyde dehydrogenase 1A1: friend or foe to female metabolism? *Nutrients* **6**, 950–973 (2014).
138. Hussain, S. *et al.* Ultrasonography-detected subclinical inflammation in patients with hand osteoarthritis and established rheumatoid arthritis: a comparison between two different pathologies using the same ultrasound examination protocol. *Musculoskeletal Care* **16**, 26-31 (2018).

139. Kortekaas M. C., Kwok W.Y., Reijniere M., Stijnen T. & Kloppenburg M. Association of Inflammation With Development of Erosions in Patients With Hand Osteoarthritis: A Prospective Ultrasonography Study. *Arthritis Rheumatol.* **68**, 392-397 (2016).
140. Lennerová, T., Pavelka, K. & Šenolt, L. Biomarkers of hand osteoarthritis. *Rheumatol. Int.* **38**, 725-735 (2018).
141. Fioravanti, A. *et al.* Can adipokines serum levels be used as biomarkers of hand osteoarthritis? *Biomarkers.* **23**, 265-270 (2018).
142. Roux, C.H. *et al.* MRI and serum biomarkers correlate with radiographic features in painful hand osteoarthritis. *Clin. Exp. Rheumatol.* **34**, 991-998 (2016).
143. Spolidoro Paschoal, N. O., Natour, J., Machado, F. S., de Oliveira, H. A. & Furtado, R. N. Effectiveness of Triamcinolone Hexacetonide Intraarticular Injection in Interphalangeal Joints: A 12-week Randomized Controlled Trial in Patients with Hand Osteoarthritis. *J. Rheumatol.* **42**, 1869-1877 (2015).
144. Lee, W. *et al.* Efficacy of hydroxychloroquine in hand osteoarthritis: a randomized, double blind, placebo-controlled trial. *Arthritis Care Res. (Hoboken)* (2017). [Epub ahead of print doi:10.1002/acr.23471].
145. Kingsbury, S.R. *et al.* Hydroxychloroquine effectiveness in reducing symptoms of hand osteoarthritis: a randomized trial. *Ann. Intern. Med.* **168**, 385-389 (2018).
146. Chevalier, X. *et al.* Adalimumab in patients with hand osteoarthritis refractory to analgesics and NSAIDs: a randomised, multicentre, double-blind, placebo-controlled trial. *Ann. Rheum. Dis.* **74**, 1697-1705 (2015).
147. Aitken, D. *et al.* A randomised double-blind placebo-controlled crossover trial of HUMira (adalimumab) for erosive hand Osteoarthritis - the HUMOR trial. *Osteoarthritis Cartilage.* (2018). [Epub ahead of print doi:10.1016/j.joca.2018.0.899]
148. Kloppenburg, M. *et al.* A phase 2a, placebo-controlled, randomized study of ABT-981, an anti-interleukin-1alpha and -1beta dual variable domain immunoglobulin, to treat erosive hand osteoarthritis (EHOA). *Ann. Rheum. Dis.* **76**, 122 (2017). [Abstract].

149. Lue, S., Koppikar, S., Shaikh, K., Mahendira, D. & Towheed, T. E. Systematic review of non-surgical therapies for osteoarthritis of the hand: an update. *Osteoarthritis Cartilage*. **25**, 1379-1389 (2017).
150. Dziedzic, K. S. *et al.* Implementing core NICE guidelines for osteoarthritis in primary care with a model consultation (MOSAICS): a cluster randomised controlled trial. *Osteoarthritis Cartilage*. **26**, 43-53 (2018).
151. Moe, R. H. Effectiveness of an Integrated Multidisciplinary Osteoarthritis Outpatient Program versus Outpatient Clinic as Usual: A Randomized Controlled Trial. *J. Rheumatol.* **43**, 411-418 (2016).
152. Arthritis Research UK/Keele University Primary Care Centre. A guidebook for people who have osteoarthritis. *Arthritis Research UK*. www.arthritisresearchuk.org/arthritis-information/keele-oa-guide.aspx (2014).
153. Jordan, K. P. *et al.* Effect of a model consultation informed by guidelines on recorded quality of care of osteoarthritis (MOSAICS): a cluster randomised controlled trial in primary care. *Osteoarthritis Cartilage*. **25**, 1588-1597 (2017). Arthritis Research UK Primary Care Centre & Keele University LINK (Lay Involvement in Knowledge Mobilisation) group. Osteoarthritis of the Hand. *Keele University*. [www.keele.ac.uk/media/keeleuniversity/ri/primarycare/OA%20Hand%20Leaflet%20v.0.10%2002.02.18%20LC%20\(1\).pdf](http://www.keele.ac.uk/media/keeleuniversity/ri/primarycare/OA%20Hand%20Leaflet%20v.0.10%2002.02.18%20LC%20(1).pdf) (2017).
154. Dziedzic, K. *et al.* Self-management approaches for osteoarthritis in the hand: a 2x2 factorial randomised trial. *Ann. Rheum. Dis.* **74**, 108-118 (2015).
155. Kjekken, I., Grotle, M., Hagen, K. B. & Østerås, N. Development of an evidence-based exercise programme for people with hand osteoarthritis. *Scand. J. Occup. Ther.* **22**, 103-116 (2015).
156. Hennig, T. *et al.* Effect of home-based hand exercises in women with hand osteoarthritis: a randomised controlled trial. *Ann. Rheum. Dis.* **74**, 1501-1508 (2015).
157. Østerås, N. *et al.* Limited effects of exercises in people with hand osteoarthritis: results from a randomized controlled trial. *Osteoarthritis Cartilage*. **22**, 1224-1233 (2014).
158. Østerås, N. Exercise for hand osteoarthritis. *Cochrane Database Syst. Rev.* **31**, CD010388 (2017).

159. Uthman, O. A. *et al.* Exercise for lower limb osteoarthritis: systematic review incorporating trial sequential analysis and network meta-analysis. *BMJ.* **347**, f5555 (2013).
160. Magnusson, K. *et al.* Body mass index and progressive hand osteoarthritis: data from the Oslo hand osteoarthritis cohort. *Scand. J. Rheumatol.* **44**, 331-336 (2015).
161. Jiang, L. Body mass index and hand osteoarthritis susceptibility: an updated meta-analysis. *Int. J. Rheum. Dis.* **19**, 1244-1254 (2016).
162. Spaans, A. J. Conservative treatment of thumb base osteoarthritis: a systematic review. *J. Hand Surg. Am.* **40**, 16-21 (2015).
163. Bertozzi, L. Investigation of the effect of conservative interventions in thumb carpometacarpal osteoarthritis: systematic review and meta-analysis. *Disabil Rehabil.* **37**, 2025-2043 (2015).
164. Goberman-Hill, R. *et al.* Designing a placebo device: involving service users in clinical trial design. *Health Expect.* **16**, 100-110 (2013).
165. Adams, J. Osteoarthritis of the thumb therapy (OTTER) trial. *University of Southampton*, https://www.southampton.ac.uk/healthsciences/research/projects/osteoarthritis_of_the_thumb_therapy.page (2018).
166. UK Clinical Trials Group (U.K.C.T.G). Osteoarthritis thumb therapy trial II. *National Institute for Health Research*, <https://ukctg.nihr.ac.uk/trials/trial-details/trial-details?trialNumber=ISRCTN54744256> (2018).
167. Bani, M. A. *et al.* A custom-made neoprene thumb carpometacarpal orthosis with thermoplastic stabilization: an orthosis that promotes function and improvement in patients with the first carpometacarpal joint osteoarthritis. *Prosthet. Orthot. Int.* **38**, 79-82 (2014).
168. Hamann, N. *et al.* Stabilization effectiveness and functionality of different thumb orthoses in female patients with first carpometacarpal joint osteoarthritis. *Clin. Biomech.* **29**, 1170-1176 (2014).
169. Grenier, M. L., Mendonca, R. & Dalley, P. The effectiveness of orthoses in the conservative management of thumb CMC joint osteoarthritis: An analysis of functional pinch strength. *J. Hand Ther.* **29**, 307-313 (2016).

170. Valdes, K., Naughton, N. & Algar, L. Linking ICF components to outcome measures for orthotic intervention for CMC OA: A systematic review. *J. Hand Ther.* **29**, 396-404 (2016).
171. Vegt, A. E. *et al.* The effect of two different orthoses on pain, hand function, patient satisfaction and preference in patients with thumb carpometacarpal osteoarthritis: a multicentre, crossover, randomised controlled trial. *Bone Joint J.* **99-B**, 237-244 (2017).
172. Watt, F. E. *et al.* Night-time immobilization of the distal interphalangeal joint reduces pain and extension deformity in hand osteoarthritis. *Rheumatology (Oxford)*. **53**, 1142-1149 (2014).
173. Hammond, A., Jones, V. & Prior Y. The effects of compression gloves on hand symptoms and hand function in rheumatoid arthritis and hand osteoarthritis: a systematic review. *Clin Rehabil.* **30**, 213-224 (2016). Fortunati, N. A., Fioravanti, A., Seri, G., Cinelli, S. & Tenti, S. May spa therapy be a valid opportunity to treat hand osteoarthritis? A review of clinical trials and mechanisms of action. *Int. J. Biometeorol.* **60**, 1-8 (2016).
174. Villafañe, J. H. & Herrero, P. Conservative treatment of Myofascial Trigger Points and joint mobilization for management in patients with thumb carpometacarpal osteoarthritis. *J. Hand Ther.* **29**, 89-92 (2016).
175. Paolillo, A. R., Paolillo, F. R., João, J. P., João, H. A. & Bagnato, V. S. Synergic effects of ultrasound and laser on the pain relief in women with hand osteoarthritis. *Lasers Med Sci.* **30**, 279-286 (2015).
176. Kloppenburg, M. *et al.* 2018 EULAR recommendations for the management of hand osteoarthritis. *Ann. Rheum. Dis.* **77**, 42 (2018).
177. Kroon, F., Kloppenburg, M., Schoones, J. & Carmona, L. Systematic literature review (SLR) for the 2018 update of the EULAR management recommendations for hand osteoarthritis (OA). *Ann. Rheum. Dis.* **77**, 1133 (2018).
178. Zou, K. *et al.* Examination of overall treatment effect and the proportion attributable to contextual effect in osteoarthritis: meta-analysis of randomised controlled trials. *Ann. Rheum. Dis.* **75**, 1964-1970 (2016).

179. Zeng C. *et al.* Relative efficacy and safety of topical non-steroidal anti-inflammatory drugs for osteoarthritis: a systematic review and network meta-analysis of randomised controlled trials and observational studies. *Br. J. Sports. Med.* **52**, 642-650 (2018).
180. Rannou, F., Pelletier, J. P. & Martel-Pelletier, J. Efficacy and safety of topical NSAIDs in the management of osteoarthritis: Evidence from real-life setting trials and surveys. *Semin. Arthritis Rheum.* **45**, S18-21 (2016).
181. Laslett, L. L. & Jones, G. Capsaicin for osteoarthritis pain. *Prog. Drug Res.* **68**, 277-291 (2014).
182. Monfort, J. *et al.* Comparative efficacy of intra-articular hyaluronic acid and corticoid injections in osteoarthritis of the first carpometacarpal joint: results of a 6-month single-masked randomized study. *Joint Bone Spine.* **82**, 116-121 (2015).
183. Jahangiri, A., Moghaddam, F. R. & Najafi, S. Hypertonic dextrose versus corticosteroid local injection for the treatment of osteoarthritis in the first carpometacarpal joint: a double-blind randomized clinical trial. *J. Orthop. Sci.* **19**, 737-743 (2014).
184. McCann, P. A., Wakeley, C. J. & Amirfeyz, R. The effect of ultrasound guided steroid injection on progression to surgery in thumb CMC arthritis. *Hand Surg.* **19**, 49-52 (2014).
185. Trellu, S., Dadoun, S., Berenbaum, F., Fautrel, B. & Gossec, L. Intra-articular injections in thumb osteoarthritis: A systematic review and meta-analysis of randomized controlled trials. *Joint Bone Spine.* **82**, 315-319 (2015).
186. Kroon, F. P., Rubio, R., Schoones, J. W. & Kloppenburg, M. Intra-Articular Therapies in the Treatment of Hand Osteoarthritis: A Systematic Literature Review. *Drugs Aging.* **33**, 119-133 (2016).
187. National Institute for Health & Care Excellence. Non-steroidal anti-inflammatory drugs (KTT13). *National Institute for Health & Care Excellence*, <https://www.nice.org.uk/advice/ktt13/resources/nonsteroidal-antiinflammatory-drugs-58757951055301> (2015).
188. Sanders, D. *et al.* Pharmacologic modulation of hand pain in osteoarthritis: a double-blind placebo-controlled functional magnetic resonance imaging study using naproxen. *Arthritis Rheumatol.* **67**, 741-751 (2015).

189. Ma, J., Talukdar, R. & Gainers-Hasugluw, V. Pilot open observations on doxycycline treatment for erosive osteoarthritis of the hand. *J. Clin. Rheumatol.* **21**, 38-39 (2015).
190. Park, J. K. *et al.* Efficacy and Tolerability of GCSB-5 for Hand Osteoarthritis: A Randomized, Controlled Trial. *Clin. Ther.* **38**, 1858-1868 (2016).
191. Watt, F. E. & Gulati, M. New drug treatments for osteoarthritis: what is on the horizon? *EMJ.* **2**, 50-58 (2017). [Review].
192. Grevan, D.E. *et al.* Preclinical characterisation of the GM-CSF receptor as a therapeutic target in rheumatoid arthritis. *Ann. Rheum. Dis.* **74**, 1924-1930 (2015)
193. US National Library of Medicine. ClinicalTrials.gov <https://clinicaltrials.gov/ct2/show/NCT02477059> (2018).
194. Singh, J. A., Noorbaloochi, S., MacDonald, R. & Maxwell, L. J. Chondroitin for osteoarthritis. *Cochrane Database Syst. Rev.* **28**, CD005614 (2015).
195. Frouzakis, R., Herren, D. B. & Marks, M. Evaluation of expectations and expectation fulfillment in patients treated for trapeziometacarpal osteoarthritis. *J. Hand Surg. Am.* **40**, 483-490 (2015).
196. Hochberg, M. C. *et al.* American College of Rheumatology 2012 recommendations for the use of nonpharmacologic and pharmacologic therapies in osteoarthritis of the hand, hip, and knee. *Arthritis Care Res. (Hoboken).* **64**, 465-474 (2012).
197. Manara, M. *et al.* Italian Society for Rheumatology recommendations for the management of hand osteoarthritis. *Reumatismo.* **65**, 167-185 (2013).
198. Kloppenburg, M. *et al.* 2018 update of the EULAR recommendations for the management of hand osteoarthritis. *Ann. Rheum. Dis.* <https://doi.org/10.1136/annrheumdis-2018-213826> (2018)
199. Kloppenburg, M. *et al.* Report from the OMERACT Hand Osteoarthritis Working Group: Set of Core Domains and Preliminary Set of Instruments for Use in Clinical Trials and Observational Studies. *J. Rheumatol.* **42**, 2190-2197 (2015).
200. Altman, R. *et al.* The American College of Rheumatology criteria for the classification and reporting of osteoarthritis of the hand. *Arthritis Rheum.* **33**, 1601-1610 (1990).

201. Riyazi, N. *et al.* Evidence for familial aggregation of hand, hip, and spine but not knee osteoarthritis in siblings with multiple joint involvement: the GARP study. **64**, 438-443 (2005)
202. Andrianakos, A.A. *et al.* Prevalence of symptomatic knee, hand, and hip osteoarthritis in Greece. The ESORDIG study. **33**, 2507-2513 (2006).
203. Castell, M.V. *et al.* Osteoarthritis and frailty in elderly individuals across six European countries: results from the European Project on OsteoArthritis (EPOSA). *BMC Musculoskelet. Disord.* **15**, 359 (2015)
204. Kellgren, J.H. & Lawrence, J. S. Radiological assessment of osteo-arthrosis. *Ann. Rheum. Dis.* **16**, 494–502 (1957).
205. Kellgren, J. H., Jeffrey, M. R. & Ball, J. *The epidemiology of chronic rheumatism. Atlas of standard radiographs of arthritis* :vii–11 (Oxford, UK: Blackwell Scientific Publications, 1963).
206. Sowers, M. *et al.* Progression of osteoarthritis of the hand and metacarpal bone loss. A twenty-year followup of incident cases. *Arthritis. Rheum.* **34**, 36-42 (1991)
207. Hochberg, M. *et al.* Bone mineral density and osteoarthritis: Data from the Baltimore Longitudinal Study of Aging. *Osteoarthritis Cartilage* **12**, 45-48 (2004)
208. Wilder, F.V., Barrett, J.P., & Farina, E.J. Joint-specific prevalence of osteoarthritis of the hand. *Osteoarthritis Cartilage.* **14**, 953-957 (2006)
209. Toba, N. *et al.* Prevalence and involvement patterns of radiographic hand osteoarthritis in Japanese women: the Hizen-Oshima Study. *J. Bone Miner. Metab.* **24**, 344-348 (2006).
210. Kalichman, L & Hernández-Molina G. Hand osteoarthritis: an epidemiological perspective. *Semin. Arthritis. Rheum.* **39**, 465-476 (2010)
211. Kämäräinen, O.P. *et al.* Aggrecan core protein of a certain length is protective against hand osteoarthritis. *Osteoarthritis Cartilage.* **14**, 1075-1080 (2006)
212. Güler-Yüksel, M. *et al.* Accelerated metacarpal bone mineral density loss is associated with radiographic progressive hand osteoarthritis. **70**, 1625-1630 (2011)
213. Hirsch, R. *et al.* Association of hand and knee osteoarthritis: evidence for a polyarticular disease subset. *Ann. Rheum. Dis.* **55**, 25-29 (1996)

214. Dahaghin, S. *et al.* Prevalence and pattern of radiographic hand osteoarthritis and association with pain and disability (the Rotterdam study). *Ann. Rheum. Dis.* **64**, 682-687 (2005)
215. Saleh, A.S. *et al.* Arterial stiffness and hand osteoarthritis: a novel relationship? *Osteoarthritis Cartilage* **15**, 357-361 (2007)
216. Stankovich, J. *et al.* Investigation of chromosome 2q in osteoarthritis of the hand: no significant linkage in a Tasmanian population. *Ann. Rheum. Dis.* **61**, 1081-1084 (2002)
217. Cooley, H.M. *et al.* The association between hormonal and reproductive factors and hand osteoarthritis. *Maturitas* **45**, 257-265 (2003)
218. Szoek, C.E.I. *et al.* Factors affecting the prevalence of osteoarthritis in healthy middle-aged women: data from the longitudinal Melbourne Women's Midlife Health Project. *Bone* **39**, 1149-1155 (2006)
219. Zhang, Y. *et al.* Prevalence of symptomatic hand osteoarthritis and its impact on functional status among the elderly: The framingham study. *American Journal of Epidemiology.* **156**, 1021-1027 (2002)
220. Hielscher, A. H, *et al.* Near-infrared diffuse optical tomography. *Dis. Markers.* **18**, 313-337 (2002).
221. Yuan, Z., Zhang, Q., Sobel, E. & Jiang, H. Comparison of diffusion approximation and higher order diffusion equations for optical tomography of osteoarthritis. *J. Biomed. Opt.* **14**, 054013 (2009).
222. Yuan, Z., leong, F. H., Jiang, H. & Sobel, E. S. Osteoarthritis and psoriatic arthritis: findings in three-dimensional biophotonics imaging. *Biomed. Mater. Eng.* **24**, 3063-3071 (2014).
223. Xi, L. & Jiang, H. Integrated photoacoustic and diffuse optical tomography system for imaging of human finger joints in vivo. *J. Biophotonics.* **9**, 213-217 (2016).
224. Etrych, T. *et al.* Fluorescence optical imaging in anticancer drug delivery. *J. Control. Release.* **226**, 168-181 (2016).
225. Werner, S. G. *et al.* Inflammation assessment in patients with arthritis using a novel in vivo fluorescence optical imaging technology. *Ann. Rheum. Dis.* **71**, 504-510 (2012).
226. Glimm, A. M., Werner, S. G., Burmester, G. R., Backhaus, M. & Ohrndorf, S. Analysis of distribution and severity of inflammation in patients with osteoarthritis compared to rheumatoid arthritis by ICG-

- enhanced fluorescence optical imaging and musculoskeletal ultrasound: a pilot study. *Ann. Rheum. Dis.* **75**, 566-570 (2016).
227. Cernohorsky, P. *et al.* In-situ imaging of articular cartilage of the first carpometacarpal joint using co-registered optical coherence tomography and computed tomography. *J. Biomed. Opt.* **17**, 060501 (2012).
228. Lynch, J. A., Hawkes, D.J. & Buckland-Wright, J. C. Analysis of texture in macroradiographs of osteoarthritic knees using the fractal signature. *Phys. Med. Biol.* **36**, 709-722 (1991).
229. Wolski, M., Podsiadlo, P., Stachowiak, G. W., Lohmander, L. S. & Englund, M. Differences in trabecular bone texture between knees with and without radiographic osteoarthritis detected by directional fractal signature method. *Osteoarthritis Cartilage.* **18**, 684-690 (2010).
230. Wolski, M., Podsiadlo, P. & Stachowiak, G. W. Directional fractal signature methods for trabecular bone texture in hand radiographs: data from the Osteoarthritis Initiative. *Med. Phys.* **41**, 081914 (2014).
231. Mhlanga, J. C., Carrino, J. A., Lodge, M., Wang, H. & Wahl, R. L. 18F-FDG PET of the hands with a dedicated high-resolution PEM system (arthro-PET): correlation with PET/CT, radiography and clinical parameters. *Eur. J. Nucl. Med. Mol. Imaging.* **41**, 2337-2345 (2014).
232. Jonsson, H. *et al.* The use of digital photographs for the diagnosis of hand osteoarthritis: the AGES-Reykjavik study. *BMC Musculoskelet. Disord.* **13**, 20 (2012).
233. Marshall, M. *et al.* Reliability of Assessing Hand Osteoarthritis on Digital Photographs and Associations with radiographic and clinical findings. *Arthritis Care Res (Hoboken).* **66**, 828-836 (2014).
234. Paradowski, P. T., Lohmander, L. S. & Englund, M. Natural history of radiographic features of hand osteoarthritis over 10 years. *Osteoarthritis Cartilage.* **18**, 917-922 (2010).
235. Chaisson, C. E. *et al.* Radiographic hand osteoarthritis: incidence, patterns, and influence of pre-existing disease in a population based sample. *J. Rheumatol.* **24**, 1337-1343 (1997).
236. Bagge, E., Bjelle, A., Valkenburg, H. A. & Svanborg, A. Prevalence of radiographic osteoarthritis in two elderly European populations. *Rheumatol. Int.* **12**, 33-38 (1992).
237. Plato, C. C. & Norris, A. H. Osteoarthritis of the hand: age-specific joint-digit prevalence rates. *Am. J. Epidemiol.* **109**, 169-180 (1979).

238. Yu, D. *et al.* Annual consultation incidence of osteoarthritis estimated from population-based health care data in England. *Rheumatology (Oxford)* **54**, 2051-2060 (2015)
239. Bijsterbosch, J. *et al.* Clustering of hand osteoarthritis progression and its relationship to progression of osteoarthritis at the knee. *Ann. Rheum. Dis.* **73**, 567-572 (2014).
240. Paradowski, P. T., Lohmander, L. S. & Englund, M. The association between metacarpal ratio, radiographic hand and knee osteoarthritis and its progression after meniscectomy. *Osteoarthritis Cartilage.* **21**, 1053-1057 (2013).
241. Yusuf, E. *et al.* Association between leptin, adiponectin and resistin and long-term progression of hand osteoarthritis. *Ann. Rheum. Dis.* **70**, 1282-1284 (2011).
242. Botha-Scheepers, S. *et al.* Progression of hand osteoarthritis over 2 years: a clinical and radiological follow-up study. *Ann. Rheum. Dis.* **68**, 1260-1264 (2009).
243. Cvijetić, S., Kurtagić, N. & Ozegović, D. D. Osteoarthritis of the hands in the rural population: a follow-up study. *Eur. J. Epidemiol.* **19**, 687-691 (2004).
244. Hassett, G., Hart, D. J., Doyle, D. V., March, L. & Spector, T. D. The relation between progressive osteoarthritis of the knee and long term progression of osteoarthritis of the hand, hip, and lumbar spine. *Ann Rheum Dis.* **65**, 623-628 (2006).
245. Marshall M, Dziedzic KS, van der Windt DA, Hay EM. A systematic search and narrative review of radiographic definitions of hand osteoarthritis in population-based studies. *Osteoarthritis Cartilage.* **16**, 219-226 (2008).

Acknowledgements

The work of M.M. and K.D. is supported by the Arthritis Research UK Primary Care Centre (20202) and the work of K.D. is part-funded by a Knowledge Mobilisation Research Fellowship (KMRF-2014-03-002) from the NIHR. The work of T.L.V. and F.E.W. is supported by the Arthritis Research UK Centre for Osteoarthritis

Pathogenesis (20205) and (the work of F.E.W.) in part by the NIHR Oxford Biomedical Research Centre. The views expressed are those of the authors and not necessarily those of the NHS, the NIHR or the Department of Health.

Author contributions

All authors contributed to substantial discussion of content, researching data, writing and reviewing and/or editing the manuscript before submission.

Competing interests

M.M. declares she no competing interests. F.E.W. declares she has received clinical study research funding from Pfizer. T.L.V. declares she was a member of a hand OA advisory board for GSK in 2017. K.D. declares she is a member of the 2018 EULAR Guidelines Committee for the management of hand OA.

Publisher's note

Springer Nature remains neutral with regard to jurisdictional claims in published maps and institutional affiliations.

Key points

- Hand osteoarthritis (OA) is highly prevalent and individuals with this condition frequently report symptoms of pain, functional limitations, and frustration in undertaking everyday activities.
- Clinical imaging is not recommended for the diagnosis or routine monitoring of patients with hand OA unless an alternative diagnosis is suspected.
- MRI and ultrasonography findings have provided insight into hand OA pathology, but further prospective studies are required to inform on how features of the disease change over time.
- Hand OA is multifactorial in aetiology with evidence for the involvement of abnormal mechanical loading and hereditary factors whereas the contribution of inflammation to pathogenesis remains contentious.
- Recommendations for core treatments in the management of hand OA should be integrated into clinical practice to improve the quality of care for patients.
- A greater understanding of the presentation, pathogenesis and disease course is needed to help provide targeted therapy with existing and new treatments .

Review criteria

The aim of this review is to update earlier reviews published in Nature Reviews Rheumatology^(Kloppenburg-2014,Kloppenburg-2011) with evidence from a search over the past 5 years for new original studies, Cochrane reviews and International Guidelines.

A search for original articles that examined hand osteoarthritis and were published between 1st Jan 2012 to 10th Oct 2017 was performed in MEDLINE. The title and abstracts were searched using the following terms: “osteoarthr\$ OR OA” AND “hand OR finger OR thumb OR interphalangeal OR inter phalangeal OR IPJ OR metacarpophalangeal OR metacarpo phalangeal OR MCP OR carpometacarpal OR carpo metacarpal OR CMC OR trapezioscaphoid OR trapezio scaphoid OR TS OR erosive OR nodal OR node”. All full-text papers and articles in the English-language were reviewed. We also searched the reference lists of identified articles for further relevant papers.

Box 1. Commonly used definitions of hand OA by category

Clinical

- ACR hand osteoarthritis (OA) criteria ²¹¹: hand pain, aching or stiffness and 3 of the following four criteria:
 - Hard tissue enlargement of 2 or more of 10 selected joints*
 - Hard tissue enlargement of 2 or more distal interphalangeal joints (DIPJ)
 - Fewer than 3 swollen metacarpophalangeal joints (MCPJ)
 - Deformity of at least 1 of 10 selected joints*

(As used in REF 212, REF 213, REF 75, REF 214 and REF 55)

Radiographic

- Kellgren–Lawrence ^{215,216} grade 2 or greater in at least one hand joint (As used in REF 217; REF 25; REF 246; REF 218; REF 219; REF 220; REF 221; REF 20; REF 75; REF 21)
- Kellgren–Lawrence grade 2 or greater in at least two hand joints (As used in REF 222 and REF 223)
- Kellgren–Lawrence grade 2 or greater in two of three groups of hand joints (DIPJs; proximal interphalangeal joints (PIPJs); first carpometacarpal joint (CMCJ) and/or scaphotrapezial joint (STJ)) (As used in REF 224, REF 225; REF 226)
- Altman atlas score ⁴⁴ of 1 or more for osteophytes or joint space narrowing in one or more hand joints (As used in REF 227; REF 228; REF 229)

Symptomatic

- Hand pain, aching or stiffness and the presence of at least one hand joint with a Kellgren–Lawrence grade 2 or greater (As used in REF 230; REF 19; REF 20)
- Hand pain, aching or stiffness and the presence of with a Kellgren–Lawrence grade 2 or greater in the same joint, with at least one hand joint affected (As used in REF 25)
- Hand joint symptoms and the presence of at least one hand joint with radiographic OA in the same hand (As used in REF 22)

*The 10 selected joints refers to the second and third DIPJ, the second and third PIPJ and the CMCJ of both hands

Box 2. Novel and alternative imaging methods in development applicable to hand OA

Diffuse optical tomography (DOT) and Photoacoustic imaging (PAI)

- In DOT, light from the near infra-red spectral region is passed through tissues and the spatial and temporal variation in light absorption and scattering is measured and used to construct tomographic images²³¹. Using 3D DOT, researchers could distinguish between distal interphalangeal joints (DIPJ) affected by osteoarthritis (OA) and healthy joints²³². After further methodological refinements, this technique could distinguish between patients with hand OA and patients with psoriatic arthritis or healthy individuals²³³. Incorporating PAI with DOT improves the image resolution enabling better differentiation of bone from soft tissue²³⁴.

Fluorescence optical imaging (FOI)

- In FOI, tissues are illuminated with a light source that can range from ultraviolet to infra-red; this light excites fluorophores that have been introduced through a fluorescence contrast media that accumulates at sites of inflammation^{235,236}. In one study investigating the use of FOI in OA, which looked at joints of the hand, the researchers noted that although similar proportions of individuals with inflammation were distinguished using FOI and grey-scale or power Doppler ultrasonography in patients with either OA or rheumatoid arthritis, a particular phase of fluorescence dye flooding in FOI (phase 2) FOI might be more informative in OA²³⁷.

Optical coherence tomography (OCT)

- OCT employs light from the infra-red end of the spectrum, which is passed through the tissues under investigation and the resulting reflections are measured and cross-sectional images produced. OCT can be used to visualise cartilage in the first carpometacarpal joint (CMCJ) and detect early changes including thickening of the cartilage and changes to the articular surface that are consistent with histology findings²³⁸. Additionally, overlaying the OCT images onto CT images can help with the visualisation of cartilage²³⁸.

Trabecular bone texture

- The texture of trabecular bone is quantifiable and changes in bone texture are observable in early OA at the knee^{239,240}. Work using directional fractal signals has now extended this finding to the smaller regions of the hands, and the use of augmented variance orientation transform (AVOT) has the potential to be useful in the early detection and prediction of hand OA²⁴¹.

Positron emission mammography (PEM)

- PEM is a nuclear medicine modality that has been used to detect or characterize breast cancer. The PEM scanner has a small field of view but is comparable to a standard Positron Emission Tomography (PET) or CT scan for evaluating hand OA²⁴².

Photographic

- A system for scoring hand OA from photographs offers an alternative method of diagnosing hand OA to a clinical or radiographic assessment and is a commonly used, reliable and valid method of scoring hand OA^{243,244}. It offers researchers a feasible alternative method of data collection, which might be of particular use for large population-based studies, or studies covering wide geographic or remote areas.

Figure 1. Features of hand OA

Photographic image of an individual's hand showing squaring of the thumb base and bony enlargement, nodes and deformity of the interphalangeal joints, and the corresponding radiograph displaying osteophytes, joint space narrowing and subchondral sclerosis at the thumb base and interphalangeal joints

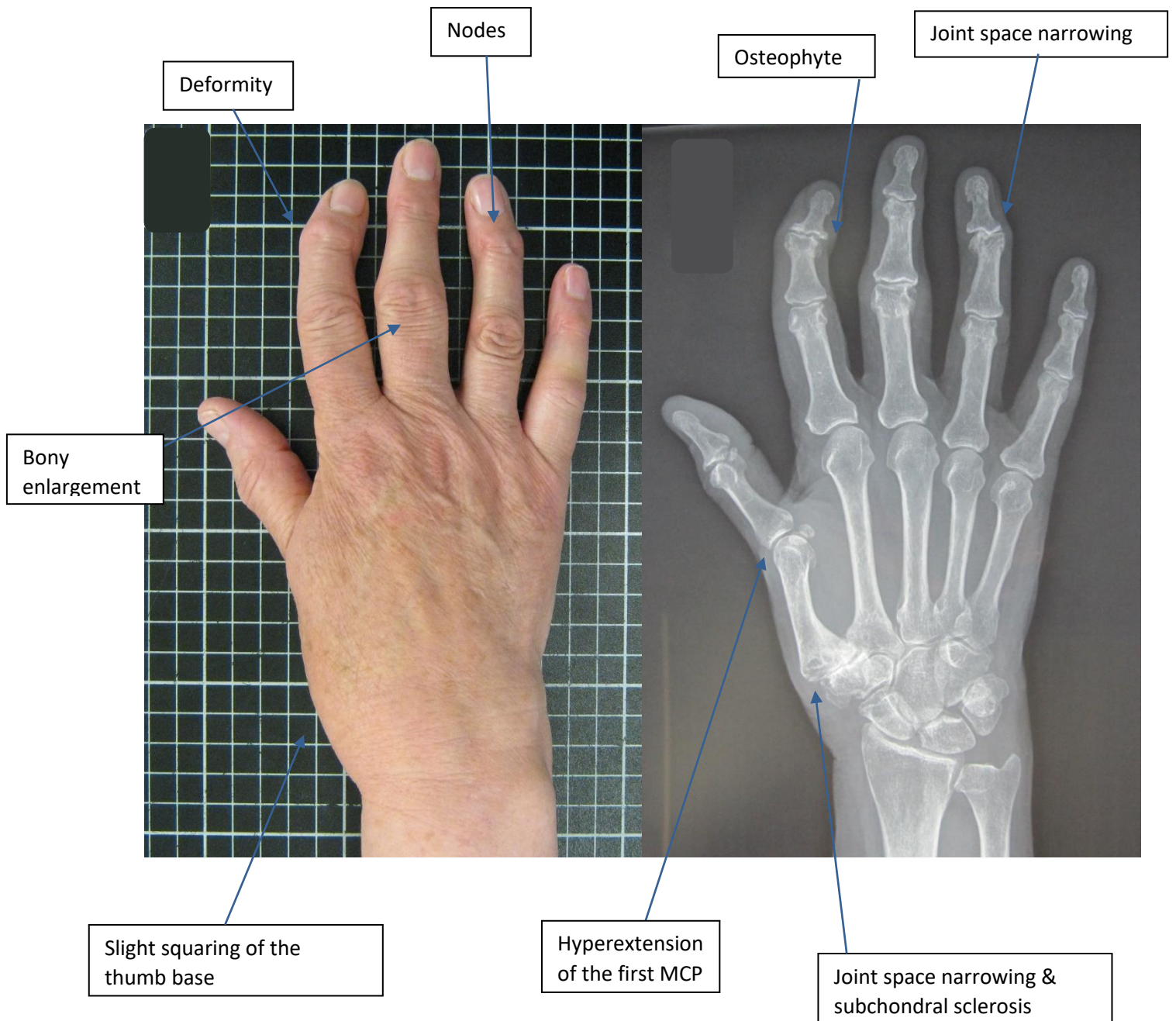
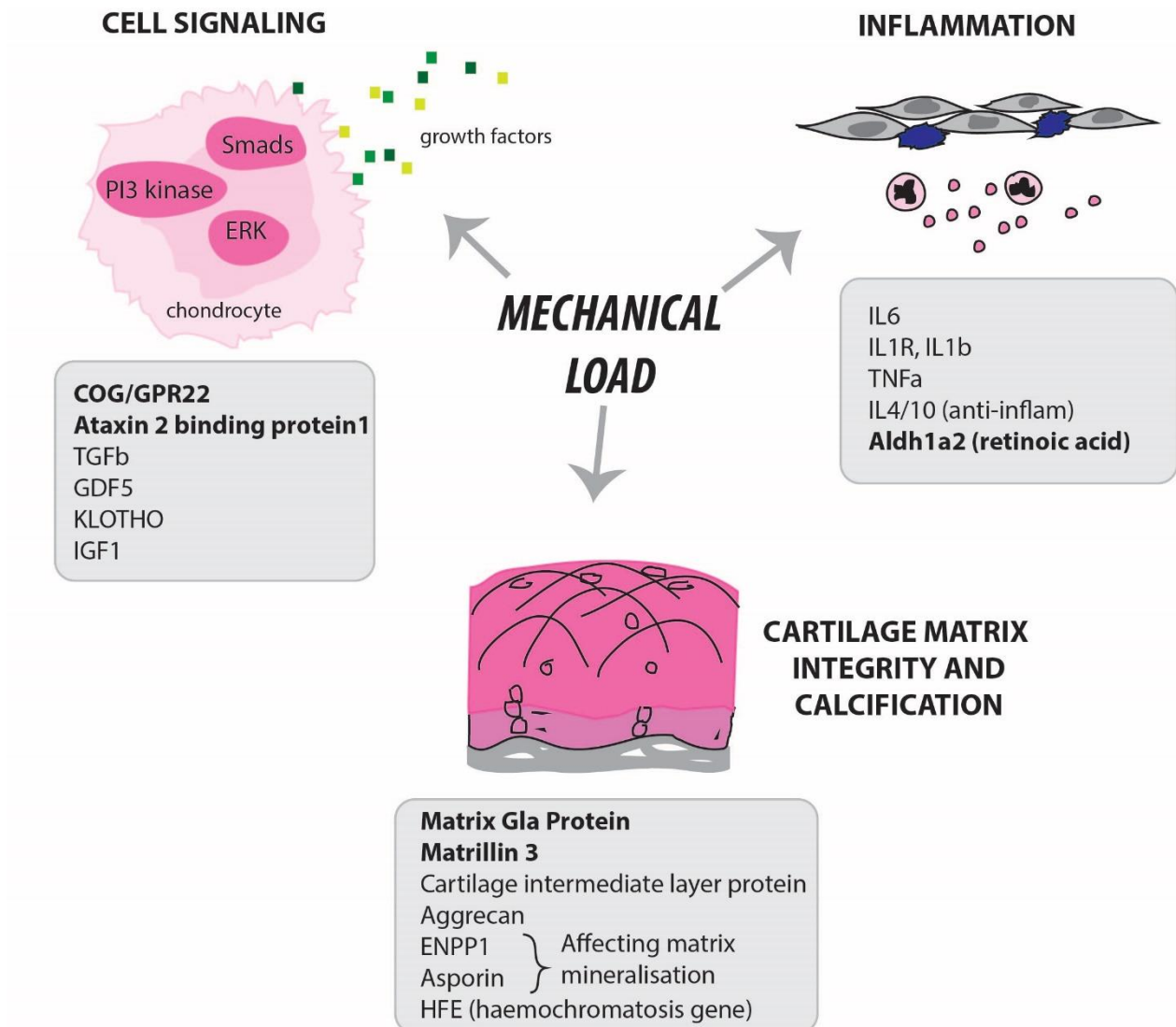


Figure 2. Predicted molecular drivers of hand OA by genetic association

Mechanical load is central to the pathogenesis of hand OA and influences growth factor bioavailability, inflammation and matrix degradation. The genes shown in this figure have been linked to radiographic or symptomatic hand OA in at least one study (some of which have not been replicated). *Genetic associations that were identified by genome wide scans (the other associations were identified using candidate gene approaches).



Extracellular signal-regulated kinase, ERK; phosphoinositide 3-kinase

Table 1. Reported incident rates for hand OA

Study	Population	Number of participants	Incidence	Follow-up time period	Annual incidence
Radiographic hand OA					
Haugen et al. (2017) ²⁴	OAI (study cohort), USA	407	18.9%	4 years	4.7%
Haugen et al.	Framingham, USA	810	Women: 34.6% Men: 33.7%	Median 8.7 (IQR 7.9-9.5) years	Women: 4.0% Men: 3.9%
Paradowski et al. (2010) ²⁴⁵	Lund, Sweden	97	14.4%	Mean 9.6 (SD 0.4) years	1.5%
Chaisson et al. (1997) ²⁴⁶	Framingham, USA	458	Overall: 83% Women: 87% Men: 76%	24 years	Overall: 3.5% Women: 3.6% Men: 3.2%
Bagge et al. (1992) ²⁴⁷	Goteborg, Sweden	74	DIPJ: 13.6% PIPJ: 13.6% First CM CJ: 4.9%	4 years	DIPJ: 3.4% PIPJ: 3.4% First CM CJ: 1.2%
Kallman et al. (1990) ²³	BLSA (study cohort), USA	84	Individuals aged <40 years: 56/1000 person years Individuals aged 40-59 years: 69/1000 person years Individuals aged ≥60 years: 106/1000 person years	Age <60: mean 23.5 (SEM ±0.25) years; Age ≥60: mean 16.9 (SEM ±0.45)	Individuals aged ≤40 years: 0.2% Individuals aged 40-59 years: 0.3%; Individuals aged ≥60 years: 0.6%
Plato et al. (1979) ²⁴⁸	BLSA (study cohort), USA	65	47.7%	Mean 13.45 (range 12-16) years	3.5%
Symptomatic hand OA					
Haugen et al. (2011) ²⁰	Framingham, USA	810	Women: 9.7% Men: 4.0%	Median 8.7 (IQR 7.9-9.5) years	Women: 1.1% Men: 0.5%
Oliveria et al. (1995) ²⁵	Massachusetts, USA	~130,000	100/100,000 person years	1 year	0.1%
Clinical diagnosis of hand OA*					
Yu et al. (2015) ²⁴⁹	CIPCA (database), UK	94,955	1.3%	1 year	1.3%

Prieto-Alhambra et al. (2014) ²⁶	SIDIAP (database), Spain	3,266,826	2.4/1000 person years	Median 4.45 (IQR 4.19-4.98) years	0.1%
---------------------------------------------	--------------------------	-----------	-----------------------	-----------------------------------	------

* Consultation rate for clinical diagnosis

OAI, Osteoarthritis Initiative; DIPJ, Distal Interphalangeal Joints; PIPJ, Proximal Interphalangeal Joints; CMCJ, Carpometacarpal Joints; IQR, Interquartile range; SD, Standard deviation; BLSA, Baltimore Longitudinal Study of Ageing; SEM, Standard error of the mean; CIPCA, Consultations in Primary Care Archive; SIDIAP, Sistema d'Informació per al Desenvolupament de la Investigació en Atenció Primària.

Table 2. Reported progression rates for hand OA

Study	Population	Number of participants	Progression	Follow-up time period	Annual progression rate
Radiographic definition (with incorporation of incidence rate)					
Haugen et al. (2017) ²⁴	OAI (study cohort), USA	994	59.4%	4 years	14.9%
Haugen et al. (2017) ²⁸	Oslo, Norway	69	62.3%	Mean 4.7 (SD 0.4) years	13.3%
Bijsterbosch et al. (2014) ²⁵⁰ and Bijsterbosch et al. (2011)	GARP (study cohort), Netherlands	236	Overall: 52.5% Osteophyte progression: 44.9% JSN progression: 25.8%	Mean 6.1 (range 5.0-7.8) years	Overall: 8.6% Osteophyte progression: 7.4% JSN progression: 4.2%
Bijsterbosch et al. (2013) ¹³²	GARP (study cohort), Netherlands	161	Overall: 60% Osteophyte progression: 53% JSN progression: 32%	6 years	Overall: 10% Osteophyte progression: 8.8% JSN progression: 5.3%
Bijsterbosch et al. (2013) ¹³²	GARP (study cohort), Netherlands	128	Overall: 39% Osteophyte progression: 24% JSN progression: 29%	2 years	Overall: 19.5% Osteophyte progression: 12% JSN progression: 14.5%
Paradowski et al. (2013) ²⁵¹ and Paradowski et al. (2010) ²⁴⁵	Lund, Sweden	118	59.3%	Mean 9.6 (SD 0.4) years	6.2%
Yusuf et al. (2011) ²⁵²	GARP (study cohort), Netherlands	164	33.5%	Mean 6.0 (SD 0.6)	5.6%
Botha-Scheepers et al. (2009) ²⁵³	GARP (study cohort), Netherlands	172	Osteophyte progression: 21.5%	2 years	Osteophyte progression: 10.8%

			JSN progression: 19.2%		JSN progression: 9.6%
Botha-Scheepers et al. (2007) ²⁷	GARP (study cohort), Netherlands	184	Osteophyte progression: 47% (probands) and 42% (siblings) JSN progression: 34% (probands) and 37% (siblings)	2 years	Osteophyte progression: 23.5% (probands) and 21% (siblings) JSN progression: 17% (probands) and 18.5% (siblings)
Cvijetić et al. (2004) ²⁵⁴	Croatia	186	DIPJ: 59.9% (women) and 54.5% (men) PIPJ: 34.9% (women) and 33.7% (men) First CMCJ: 41.2% (women) and 49.9% (men)	10 years	DIPJ: 6.0% (women) and 5.5% (men) PIPJ: 3.5% (women) and 3.4% (men) First CMCJ: 4.1% (women) and 5.0% (men)
Kallman et al. (1990) ²³	BLSA (study cohort), USA	177	Individuals aged <40 years: 50% Individuals aged 40-59 years: 50% Individuals aged ≥60 years: 50%	15.8 years; 12.4 years; 8.9 years	Individuals aged <40 years: 3.2% Individuals aged 40-59 years: 4.0% Individuals aged ≥60 years: 5.6%
Radiographic definition (without incorporation of incidence rate)					
Haugen et al. (2011) ²⁰	Framingham, USA	464	Women: 96.4% Men: 91.4%	Median 8.7 (IQR 7.9-9.5) years	Women: 11.1% Men: 10.5%
Güler-Yüksel et al. (2011) ²²³	GARP (study cohort), Netherlands	181	31.7%	2 years	15.9%

Hassett et al. (2006) ²⁵⁵	Chingford, UK	Osteophytes: 222 JSN: 308	Osteophyte progression: 72.5%;	11 years	Osteophyte progression: 6.6% JSN progression: 5.8%
Plato et al. (1979) ²⁴⁸	BLSA (study cohort), USA	29	72.4%	Mean 13.45 (range 12-16) years	5.4%
MRI-based definition (with incorporation of incidence rate)					
Haugen et al. (2017) ²⁸	Oslo, Norway	69	58.0%	Mean 4.7 (SD 0.4) years	12.3%

Abbreviations: GARP, Genetics, Arthrosis and Progression; JSN, Joint space narrowing; OAI, Osteoarthritis Initiative; SD, Standard deviation; IQR, Interquartile range; DIPJ, Distal Interphalangeal Joints; PIPJ, Proximal Interphalangeal Joints; CM CJ, Carpometacarpal Joints; BLSA, Baltimore Longitudinal Study of Ageing; MRI, Magnetic Resonance Imaging.

-Online only**Competing interests**

Michelle Marshall has no competing interests to declare. Fiona Watt has received clinical study research funding from Pfizer. Tonia Vincent was a member of a hand OA advisory board for GSK in 2017. Krysia Dziejczak is a member of the 2018 EULAR Guidelines Committee for the management of hand OA.

Subject categories

[Health sciences / Rheumatology / Rheumatic diseases / Osteoarthritis](#)

[URI /692/4023/1670/407]

[Health sciences / Health care / Public health / Epidemiology](#)

[URI /692/700/478/174]

[Health sciences / Pathogenesis](#)

[URI /692/420]

[Health sciences / Health care / Therapeutics](#)

[URI /692/700/565]

[Health sciences / Health care](#)

[URI /692/700]

TOC

Hand osteoarthritis (OA) is a heterogeneous and prevalent condition involving multiple joints. In this Review, the authors provide an update on the epidemiology, presentation and burden of hand OA, as well as advances in imaging techniques, disease management and pathogenesis.