



Research Journal of
Parasitology

ISSN 1816-4943



Academic
Journals Inc.

www.academicjournals.com



Research Article

First Detection of *Leishmania infantum* in Domestic Dogs from Burkina Faso (West Africa)

^{1,2,3}Ibrahim Sangaré, ^{2,3}Arthur Djibougou Djibougou, ¹Bienvenue Koudraogo Yaméogo, ⁴François Drabo, ^{1,3}Abdoulaye Diabaté, ⁵Anne-Laure Banuls, ^{1,5}Florence Fournet, ⁶Helen Price, ^{2,3}Robert Tinga Guiguemé and ^{1,3}Roch Kounbobr Dabiré

¹Institut de Recherche en Sciences de la Santé, Direction Régionale de l'ouest, 399 avenue de la liberté, 01 BP545 Bobo-Dioulasso 01, Burkina Faso

²Institut Supérieur des Sciences de la Santé, Université Polytechnique de Bobo-Dioulasso, 01 BP1091, Bobo-Dioulasso, Burkina Faso

³Centre Muraz, Unité Paludisme et Maladies Tropicales Négligées, Bobo-Dioulasso, Burkina Faso

⁴Ministère de la Santé, Direction de la Lutte contre la Maladie, Coordination de la lutte contre les Maladies tropicales Négligées, Ouagadougou, Burkina Faso

⁵Institut de Recherche pour le Développement, unité MIVEGEC (UM1-UM2-CNRS 5290-IRD 224), 911 avenue Agropolis, 34394 Montpellier, Cedex 5, France

⁶Faculty of Natural Sciences, Keele University, Keele, Staffordshire, ST5 5BG, UK

Abstract

Background and Objective: Human Visceral Leishmaniasis (HVL) is a systemic neglected tropical disease and potentially lethal disease caused by infection with protozoan parasites of the *Leishmania* genus. In the causal, agent of HVL is *L. infantum* and dogs are a major reservoir host. Visceral leishmaniasis is rarely found in West Africa and no cases have been reported to date in Burkina Faso. The purpose of the current study was to investigate the presence of *L. infantum* in population of domestic dogs in Bobo-Dioulasso city in Burkina Faso. **Materials and Methods:** The study was carried out in five districts of the city Bobo-Dioulasso, Burkina Faso. An active survey was conducted in households with dogs in five districts of the city for canine leishmaniasis screening. Epidemiological data and clinical signs were collected for each dog. Venous blood collection and skin lesions biopsies were performed in dogs after informed consent of the owners. The plasma was used for the immunological diagnosis (DiaMed-IT LEISH) and positive samples were confirmed by nested PCR. **Results:** A total of 85 dogs were included in the study. For the first time, the occurrence of *L. infantum* in Burkina Faso was confirmed in five domestic dogs presenting symptomatic signs by immunochromatographic tests. Biopsy samples were positive for *L. infantum* in PCR analysis. **Conclusion:** The findings indicated that *L. infantum* is circulating within canine populations in Bobo-Dioulasso. Infected dogs would be the reservoir hosts of this visceralising species. Several priorities for public and veterinary health research have been highlighted by this study.

Key words: *Leishmania infantum*, canine reservoir, Burkina Faso, human visceral leishmaniasis

Received: August 30, 2016

Accepted: November 04, 2016

Published: December 15, 2016

Citation: Ibrahim Sangaré, Arthur Djibougou Djibougou, Bienvenue Koudraogo Yaméogo, François Drabo, Abdoulaye Diabaté, Anne-Laure Banuls, Florence Fournet, Helen Price, Robert Tinga Guiguemé and Roch Kounbobr Dabiré, 2017. First detection of *Leishmania infantum* in domestic dogs from Burkina Faso (West Africa). Res. J. Parasitol., 12: 27-32.

Corresponding Author: Ibrahim Sangaré, Institut Supérieur des Sciences de la Santé, Université Polytechnique de Bobo-Dioulasso, 01 BP1091, Bobo-Dioulasso, Burkina Faso Tel: +22670085167

Copyright: © 2017 Ibrahim Sangaré *et al.* This is an open access article distributed under the terms of the creative commons attribution License, which permits unrestricted use, distribution and reproduction in any medium, provided the original author and source are credited.

Competing Interest: The authors have declared that no competing interest exists.

Data Availability: All relevant data are within the paper and its supporting information files.

INTRODUCTION

Protozoan parasites of the *Leishmania* genus are the aetiological agents of a group of diseases known as the leishmaniasis. These diseases exist in both anthroponotic and zoonotic forms, depending largely on parasite species and geographical location. Many epidemics of visceral, muco-cutaneous and cutaneous leishmaniasis have been reported in human populations¹. There are approximately 2 million new cases of leishmaniasis in humans per year, representing a significant burden on global health².

Human Cutaneous Leishmaniasis (HCL) is endemic in Burkina Faso and broadly in West Africa, due to infection with the zoonotic species *L. major*³⁻¹⁰. The HCL is usually self-healing in immunocompetent individuals, although this can take a year or longer. In contrast, the more severe systemic infection of Human Visceral Leishmaniasis (HVL) is fatal unless treated, thus constituting a major global public health problem that affects an estimated 500,000 people annually. Whereas the extent of visceral leishmaniasis is well documented in North and East Africa, very limited data have been recorded on its occurrence and spread in West Africa¹¹ and no cases have been found in Burkina Faso. In North Africa, the pathogenic agent is *L. infantum* and the main reservoir hosts reported to date are domestic dogs¹². In East Africa, the main pathogenic agent is *L. donovani* and the disease is considered to be anthroponotic¹³.

In West Africa, the probable causal agent of HVL is *L. infantum*, transmitted by Phlebotominae sandflies, which are distributed in both wild and domestic ecosystems¹⁴. Previous studies identified the primary vectors of *L. infantum* to be *Phlebotomus ariasi*, *Phlebotomus perniciosus* and *Phlebotomus longicuspis*^{5,16} with domestic dogs (*Canis familiaris*) acting as the main reservoirs¹⁴. In fact, it has been estimated that more than 50% of seropositive dogs are asymptomatic¹⁷, suggesting that the prevalence of this infection may be underestimated. A high level of infected dogs may significantly increase the risk of emergence of HVL, especially in peripheral urban areas¹⁸. Effective monitoring of the canine population, the most likely parasite reservoir, is crucial in order to limit the emergence of this disease (HVL) in human populations.

In Burkina Faso, a number of HCL cases have been reported, with *L. major* as the causative agent. However no sandflies have been found which are infected by this parasite, despite sampling *Phlebotomus duboscqi* which is suspected to be the main vector in West Africa¹⁹. Another important

vector species, *P. longicuspis*, which transmits *L. infantum*, has been captured in Ouagadougou but no *Leishmania* infected flies have been isolated²⁰.

Many experts have presumed that the lack of reported cases of HVL may be ascribed to a differential diagnosis between this and other infectious diseases including malaria, toxoplasmosis and schistosomiasis, which may present with similar symptoms of severe anemia, hepatosplenomegaly and unexplained fever.

This study advanced on new knowledge on leishmaniasis epidemiology by integrating the presence of *L. infantum*, agent of HVL, in addition to *L. major*.

In this context, five cases of canine leishmaniasis due to *L. infantum* infection, identified in Bobo-Dioulasso, the second town of Burkina Faso, located in the Southwestern part of the country have been reported for the first time. Detection of *L. infantum* in the main reservoir host of this parasite highlighted a new potential risk of HVL in this region.

MATERIALS AND METHODS

Study sites and design: The study was carried out in five districts (Belle-Ville, Koden, Koua, Nieneta and Sarfalao) of the city Bobo-Dioulasso in Burkina Faso (Fig. 1). The study sites are representative of the environment of the city which is characterized by the presence of vegetable cropping. The annual rainfall ranges from 1,000 to 1,200 mm.

An active survey was conducted in households with dogs in five districts of the city for canine leishmaniasis screening. Samples were collected following consent from the owner of each dog. Epidemiological data (age, sex and location) were collected for each animal. Symptoms including skin lesions, exfoliative dermatitis, cachexia, low appetite, alopecia and ocular lesions were also registered for each dog.

A total of 85 dogs were included in the study: 49 dogs in Sakaby, 21 in Sarfalao, 9 in Belle-Ville, 4 in Koden and 2 in Koua.

Blood collection, cutaneous biopsy and diagnosis method:

Blood (2-5 mL) was taken from dogs by venipuncture and collected in sterile EDTA-containing tubes. Samples were stored at 4°C for 4-10 h before centrifugation at 1500-1800 g for 20 min.

Cutaneous biopsies of lesions were performed using sterile lancets and samples stored in sterile tubes at -20°C. Buffy coat fractions containing leukocytes were removed, added to 10 mM Tris-HCl buffer in a 1:1 proportion, then stored at -20°C. Buffy coats and cutaneous biopsy samples were subjected to DNA extraction using a DNeasy Blood and Tissue kit (Qiagen, Valencia, CA).

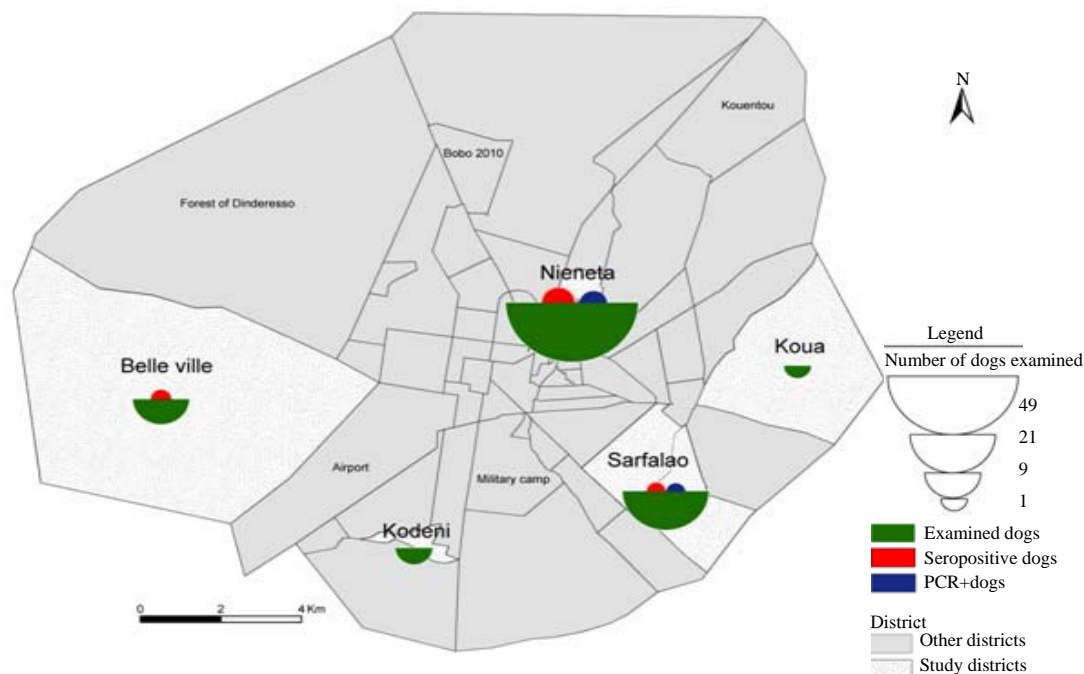


Fig. 1: Map of study areas in Bobo-Dioulasso

Plasma samples were used for serological diagnostic tests (DiaMed-IT LEISH, Cressier sur Morat, Switzerland) according to the manufacturer’s instructions.

PCR analysis: Seropositive specimens were confirmed by PCR using the protocol of Cassan *et al.*²¹. The PCR reactions were used to target the *Leishmania* kinetoplast DNA (kDNA). Reaction 1 was performed using primers CSB2XF (5'-CGAGTAGCAGAACTCCCGTTCA-3') and CSB1XR (5'-ATTTTCGCGATTTTCGAGAACG-3'). Reaction 2 was performed using primers 13Z (5'-ACTGGGGGTTG GTGAAAATAG-3') and LIR (5'-TCGCAGAACGCCCT-3').

The PCR cycle conditions were: 1 cycle at 94°C for 2 min, followed by 45 cycles at 94°C for 30 sec, 54°C for 60 sec, 72°C for 60 sec and 72°C for 10 min. Amplified products were analyzed on 1.5% agarose gels and visualized using ethidium bromide. This method is highly sensitive and can be used to distinguish between DNA from different *Leishmania* species. Expected product sizes were 560 bp for *L. major*, 680 bp for *L. infantum/L. donovani* and 750 bp for *L. tropica*.

RESULTS

Serological tests identified *Leishmania* infection in 5 dogs presenting symptomatic signs. They were found in Belle-Ville (1 case), Sarfalao (1 case) and Nieneta (3 cases).

These districts are characterized by a rural environment where urban agriculture is practiced.

The infected dogs were identified as local race and had never moved outside the Bobo-Dioulasso. Specific details of seropositive cases are as follows:

- Case 1:** From Belle-Ville, the *L. infantum* positive dog was a 6-year-old male. Clinical examination showed alopecia on the ears and exfoliative dermatitis (Fig. 2a). According to the owner, the dog had shown progressive loss of weight with decreased appetite
- Case 2:** From Sarfalao, this case was a 4-year-old male with observed alterations to the ears 6 months previously (Fig. 2b)

The other three cases were located in Nieneta:

- Case 3:** A 3-year-old female. Clinical examination showed auricular ulcerative lesions (Fig. 2c)
- Case 4:** Also a 3-year-old female with generalized alopecia on the skin and auricular ulcerative lesions. The animal had shown severe loss of weight with decreased appetite (Fig. 2d)
- Case 5:** Corresponded to a 10-year-old male dog showing a generalized alopecia and hyperkeratosis on skin. This case also had auricular lesions (Fig. 2e)

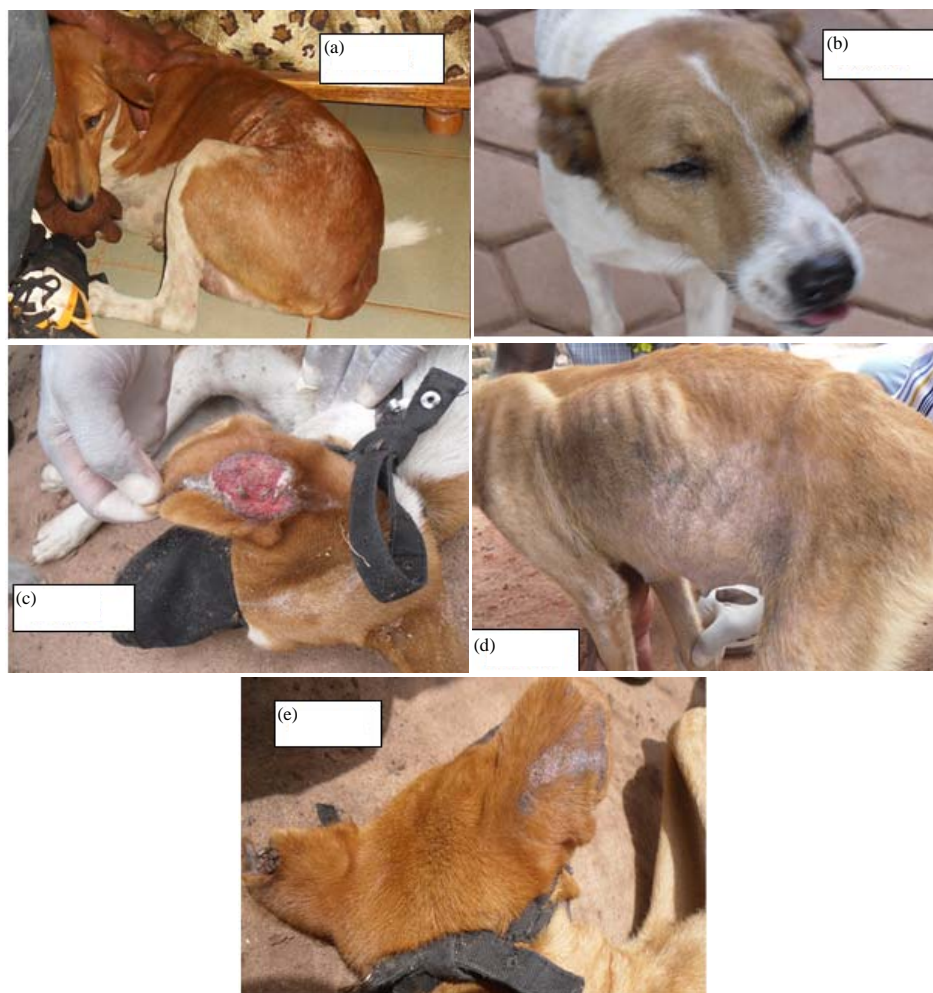

Fig. 2 (a-e): Images of dogs showing different cutaneous lesions and symptoms, (a) Case 1, (b) Case 2, (c) Case 3, (d) Case 4 and (e) Case 5

To confirm the results and to identify the species, PCR analysis was performed on buffy coat samples (all cases) and cutaneous biopsy samples (all cases except Case 1 which did not have open lesions). Biopsy samples were positive for *L. infantum* in 3 of the seropositive dogs (Case 2, 3 and 4) (Fig. 3). Only one buffy coat sample (Case 3) was positive.

DISCUSSION

This study aimed to screen the presence of *L. infantum* infection in the domestic dog in Burkina Faso. For the first time, the occurrence of *L. infantum* in Bobo-Dioulasso city was observed in five domestic dogs by immunochromatographic tests and three were confirmed by kDNA nested PCR.

The positive serological tests were confirmed by PCR analysis from biopsy samples, indicating that parasitaemia was higher in cutaneous biopsy samples than venous blood samples. Indeed the other venous blood samples were negative to PCR as found in previous studies that did not find positive PCR from venous blood samples. The sensitivity of this test showed some variability because the protozoan distribution is not equal in the same tissues from different individuals²². Parasitaemia appeared to be highest in cutaneous biopsy samples of dogs²³ as observed in the results.

This finding suggested that infected dogs constitute the reservoir of *L. infantum*. The insect vector of *L. infantum* was reported to be *P. longicuspis* which might be present in Burkina Faso²⁰. Human visceral leishmaniasis was not



Fig. 3: PCR analysis of biopsy and blood samples from seropositive dogs

1: DNA molecular weight marker (100 bp), 2: Positive control for *L. infantum* (680 bp), 3: Positive control for *L. major*, 4: Positive control for *L. tropica*, 5: Case 2, skin biopsy, 6: Case 2, buffy coat, 7: Case 3, skin biopsy, 8: Case 3, buffy coat, 9: Case 4, skin biopsy, 10: Case 4, buffy coat, 11: Case 5, skin biopsy, 12: Case 5, buffy coat, 13: Case 1, buffy coat, 14: Negative control PCR1, 15: Negative control PCR2, Blue line: *L. infantum*, Green line: *L. major* and Pink line: *L. tropica*

routinely diagnosed in West Africa¹⁹. It is possible that clinicians are misdiagnosing cases of this disease and confusing symptoms with malaria, toxoplasmosis, or another infectious fever.

M. Koura Dofinita, local representative of Provincial Animal Health Ministry. We also thank to all staff members of Animal Health Care Centers of Bobo-Dioulasso and the dog owners that participated in this study for their cooperation.

CONCLUSION AND RECOMMENDATIONS

This study revealed the presence of agent of visceral leishmaniasis in Burkina Faso. It is therefore a clinical emergency for health authorities to add human visceral leishmaniasis in the list of infections diseases to be investigated in the country. A viewpoint of basic research, DNA sequencing analysis of positive samples are necessary to allow to do the phylogeny of *L. infantum* strain found in Burkina Faso.

Several priorities for public health research are highlighted by this study. Further studies are required using molecular diagnostic tools and involving cooperation with veterinary services in one health approach, in order to better address the spatial distribution of this disease in humans and canines and other potential reservoirs. It is also crucial to perform entomological surveys to characterize the Phlebotominae vectors of leishmaniasis in the area, in order to plan control strategy of this infection in Burkina Faso.

ACKNOWLEDGMENTS

We would like to thank M. Zida, veterinary lab technician, who helped in the collection of blood samples and

REFERENCES

1. Ready, P.D., 2014. Epidemiology of visceral leishmaniasis. Clin. Epidemiol., 6: 147-154.
2. Alvar, J., I.D. Velez, C. Bern, M. Herrero and P. Desjeux *et al.*, 2012. Leishmaniasis worldwide and global estimates of its incidence. PloS ONE, Vol. 7. 10.1371/journal.pone.0035671.
3. Harrat, Z., F. Pratlong, R. Benikhlef, P. Lami, M. Belkaid and J.P. Dedet, 1998. Leishmania major MON-74 as a causative agent of cutaneous leishmaniasis in Burkina Faso. Trans. R. Soc. Trop. Med. Hyg., 92: 355-355.
4. Barro-Traore, F., L. Preney, A. Traore, H. Darie and P. Tapsoba *et al.*, 2008. [Cutaneous leishmaniasis due to *Leishmania major* involving the bone marrow in an AIDS patient in Burkina Faso]. Annales de Dermatologie et de Venereologie, 135: 380-383.
5. Guiguemde, R.T., O.S. Sawadogo, C. Bories, K.L. Traore and D. Nezien *et al.*, 2003. *Leishmania major* and HIV co-infection in Burkina Faso. Trans. R. Soc. Trop. Med. Hyg., 97: 168-169.
6. Niamba, P., O. Goumbri-Lompo, A. Traore, F. Barro-Traore and R.T. Soudre, 2007. Diffuse cutaneous leishmaniasis in an HIV-positive patient in Western Africa. Aust. J. Dermatol., 48: 32-34.
7. Sakande, B., S.S. Traore, J. Kabore, T. Ouattara and R.B. Soudre, 1998. [Human parasitoses in Burkina Faso. Histopathologic approach]. Bull. Soc. Pathol. Exot., 91: 217-220, (In French).

8. Traore, K.S., N.O. Sawadogo, A. Traore, J.B. Ouedraogo, K.L. Traore and T.R. Guiguemde, 2001. [Preliminary study of cutaneous leishmaniasis in the town of Ouagadougou from 1996 to 1998]. Bull. Soc. Pathol. Exot., 94: 52-55, (In French).
9. Bamba, S., A. Gouba, K.M. Drabo, D. Nezien, M. Bougoum and T.R. Guiguemde, 2011. [Trends in incidence of cutaneous leishmaniasis from 1999 to 2005 in Ouagadougou, Burkina]. Med. Trop. (Mars), 71: 312-312.
10. Kweku, M.A., S. Odoom, N. Pupilampu, K. Desewu and G.K. Nuako *et al.*, 2011. An outbreak of suspected cutaneous leishmaniasis in Ghana: lessons learnt and preparation for future outbreaks. Global Health Action, Vol. 4. 10.3402/gha.v4i0.5527.
11. Faye, B., B. Bucheton, A.L. Banuls, M.W. Senghor and A.A. Niang *et al.*, 2011. Seroprevalence of *Leishmania infantum* in a rural area of Senegal: Analysis of risk factors involved in transmission to humans. Trans. R. Soc. Trop. Med. Hyg., 105: 333-340.
12. Benbella, I., F. Aich, M. Elkhayat, H. Khalki and A. Khermach *et al.*, 2016. Visceral leishmaniasis in adults: About twelve cases. Pan Afr. Med. J., Vol. 23. 10.11604/pamj.2016.23.194.8921.
13. Tonui, W.K., 2006. Situational analysis of leishmaniasis research in Kenya. Afr. J. Health Sci., 13: 7-21.
14. Faye, B., A.L. Banuls, B. Bucheton, M.M. Dione and O. Bassanganam *et al.*, 2010. Canine visceral leishmaniasis caused by *Leishmania infantum* in Senegal: Risk of emergence in humans? Microb. Infect., 12: 1219-1225.
15. Barhoumi, W., W. Fares, S. Cherni, M. Derbali and K. Dachraoui *et al.*, 2016. Changes of sand fly populations and *Leishmania infantum* infection rates in an irrigated village located in arid central Tunisia. Int. J. Environ. Res. Public Health, Vol. 13. 10.3390/ijerph13030329.
16. Alcolea, P.J., A. Alonso, M.A. Degayon, M. Moreno-Paz, M. Jimenez, R. Molina and V. Larraga, 2016. *In vitro* infectivity and differential gene expression of *Leishmania infantum* metacyclic promastigotes: Negative selection with peanut agglutinin in culture versus isolation from the stomodeal valve of *Phlebotomus perniciosus*. BMC Genomics, Vol. 17. 10.1186/s12864-016-2672-8.
17. Mohebali, M., H. Hajjaran, Y. Hamzavi, I. Mobedi and S. Arshi *et al.*, 2005. Epidemiological aspects of canine visceral leishmaniasis in the Islamic Republic of Iran. Vet. Parasitol., 129: 243-251.
18. Baneth, G., A.F. Koutinas, L. Solano-Gallego, P. Bourdeau and L. Ferrer, 2008. Canine leishmaniasis-new concepts and insights on an expanding zoonosis: Part one. Trends Parasitol., 24: 324-330.
19. Coulibaly, C.A., I. Sissoko, B. Traore, A. Diallo, S. Samake, S.F. Traore and S. Doumbia, 2016. Diversity of sand flies (Diptera: Psychodidae: Phlebotominae) in two different eco-climatic and endemic zones of cutaneous Leishmaniasis in Mali, West Africa. J. Med. Entomol., 53: 923-927.
20. Depaquit, J., F. Muller, J.C. Gantier, N. Leger, H. Ferte, P. Ready and A.A. Niang, 2005. Phlebotomine sand flies from Ouagadougou, Burkina Faso: First record of *Phlebotomus (Larroussius) longicuspis* South of the Sahara. Med. Vet. Entomol., 19: 322-325.
21. Cassan, C., M.M. Dione, J. Dereure, S. Diedhiou and B. Bucheton *et al.*, 2016. First insights into the genetic diversity and origin of *Leishmania infantum* in Mont Rolland (Thies region, Senegal). Microb. Infect., 18: 412-420.
22. Reithinger, R. and J.C. Dujardin, 2007. Molecular diagnosis of leishmaniasis: Current status and future applications. J. Clin. Microbiol., 45: 21-25.
23. Baneth, G., Y. Nachum-Biala, M.S. Simon, O. Brenner, S. Gaier, A. Rojas and D. Yasur-Landau, 2016. *Leishmania major* infection in a dog with cutaneous manifestations. Parasites Vectors, Vol. 9. 10.1186/s13071-016-1541-2.